

**Joint Pathology Center
Veterinary Pathology Services
Wednesday Slide Conference
2011-2012
Conference 17
07 March 2012**

Signalment: 2-year 5-month-old, female, domestic shorthair cat, feline (*Felis domesticus*).

History: This young adult cat lived in a rural area in northern Scotland, United Kingdom, and had a history of hunting small birds. In January 2006, it became dull and anorexic for 24 hours. The cat began showing signs of distress and abdominal discomfort, then vomited yellow material. It developed seizures and died 36 hours after the onset of clinical signs. An in-contact cat was unaffected.

Gross Pathology: At postmortem examination, the cat had dilatation and thickening of several 1cm long segments of the jejunum and a 3cm long segment of the ileum.

Laboratory Results: Bacteriology: *Salmonella enterica* serovar typhimurium, phage type DT40, was recovered in profuse growth from the small intestine.

Virology: Intestinal contents were negative for feline parvovirus by the polymerase chain reaction.

Contributor's Histopathologic Description: Intestine (Ileum and caecum). The mucosa of the ileum is eroded and there is necrosis, with exudation of neutrophils and necrotic cellular debris into the intestinal lumen. Destruction of villi and crypts is evident. The intestinal lamina propria is extensively infiltrated with neutrophils and sheets of macrophages, producing a pyogranulomatous inflammatory reaction. Bacteria are present on the luminal surface of the mucosa and also infiltrate the lamina propria. Less severe changes are present in the caecum.

Lymph node. The subcapsular, intertrabecular and medullary sinuses of the ileocaecal lymph node are infiltrated with macrophages and lesser numbers of neutrophils, producing a pyogranulomatous inflammatory reaction, and there is focal necrosis in some areas.

Contributor's Morphologic Diagnosis: Intestine: Enteritis, segmental, severe, necrotising, pyogranulomatous, with bacterial colonisation and invasion, consistent with enteric salmonellosis (*Salmonella enterica* serovar typhimurium, phage type DT40), domestic shorthair, feline
Ileocaecal lymph node: Lymphadenitis, moderate, multifocal, locally extensive, pyogranulomatous, consistent with salmonellosis.

Contributor's Comment: The clinical signs and pathological findings in this cat were consistent with fatal enteric salmonellosis. The isolate of *Salmonella enterica* serovar typhimurium obtained from the affected cat was phage typed as the definitive type (DT) 40. This strain is associated with wild birds, particularly finches (family *Fringillidae*), in North America, Europe and Scandinavia^{2,4,5,8}. The cat had a history of hunting wild birds, which represents the likely source of infection.

An outbreak of gastroenteritis due to *S. typhimurium* DT40 in cats and humans in central Sweden in 1999 was associated with infection and mortality in wild birds, notably common redpolls (*Carduelis flammea*) and Eurasian siskins (*Carduelis spinus*)⁸. In the United Kingdom, *S. typhimurium* DT40 has been isolated from European greenfinches (*Carduelis chloris*), house sparrows (*Passer domesticus*), chaffinches (*Fringilla coelebs*) and European goldfinches (*Carduelis carduelis*), in decreasing order of frequency, as well as occasionally from other species of birds⁴. *S. typhimurium* DT40 has also been associated with epizootics of mortality in wild birds from winter 1997 to

summer 1998 in eastern North America, including the Canadian Atlantic maritime provinces of New Brunswick, Nova Scotia, Prince Edward Island, Newfoundland and Labrador². The species most commonly affected in North America were common redpolls (*Carduelis flammea*), pine siskins (*Carduelis pinus*), purple finches (*Carpodacus purpureus*), evening grosbeaks (*Coccothraustes vespertinus*) and American goldfinches (*Carduelis tristis*), in decreasing order of frequency. *S. typhimurium* DT40 is considered to be an avian-adapted strain with a relatively narrow host range and a wide geographical distribution⁵. Wild bird strains of *S. typhimurium* (DT2, DT40, DT41, DT56 variant, DT99 and DT195) have been isolated at relatively low frequency from domestic livestock in the United Kingdom, but appear to be uncommon in humans, cats or dogs⁴.

The most common source of infection with *S. typhimurium* in cats is from the consumption of raw meat⁶. Healthy cats, as well as sick cats without enteric disease, may carry *S. typhimurium*, which is a potential zoonosis, although the reported prevalence of infection varies widely^{7,9}. Cats may also be a source of antimicrobial resistant *S. typhimurium*⁹. The isolate of *S. typhimurium* DT40 from the cat reported here was resistant to streptomycin and sulphafurazole, but sensitive to ampicillin, clavulanate-potentiated amoxicillin, enrofloxacin, chloramphenicol, furazolidone, neomycin, oxytetracycline, and trimethoprim-sulphonamide, so was not considered to be a multi-drug resistant strain.

JPC Diagnosis: 1. Ileum: Enteritis, necrotizing and pyogranulomatous, diffuse, moderate to severe, with marked lymphoid necrosis and crypt regeneration.
2. Lymph node: Lymphadenitis, necrotizing and pyogranulomatous, diffuse, moderate to severe, with marked lymphoid necrosis.

Conference Comment: Lymphoid necrosis of the Peyer's patches and lymph node is a prominent feature in this case, and is consistent with the pathogenesis of *Salmonella*, which invade M cells in the Peyer's patches and epithelium of the distal small intestine, cecum, upper colon, and tonsils. Virulence factors include fimbriae (pilar adhesins), which are important for colonization and receptor mediated endocytosis; flagella which enhance movement and facilitate attachment; enterotoxins that produce secretory diarrhea by blocking closure of chloride channels; and bacterial wall lipopolysaccharides (endotoxins) that cause membrane injury and cell death. These endotoxins are composed of an O-specific side chain which is unique to each bacterial species, and a Lipid A core which activates mononuclear phagocytes and induces the production of tumor necrosis factor (TNF) and interleukin-1 (IL-1). This, in turn, induces endothelial cells to produce IL-6 and IL-8 and induce adhesion molecules, thus participating in leukocyte recruitment. Once adhered to macrophages, the bacteria inject bacterial proteins by a type III secretion system. *Salmonella* sp. also induce apoptosis of macrophages by a type I secretory system which activates caspase-1. The resulting pattern of injury includes acute coagulative necrosis of enterocytes and vasculitis with thrombosis in the lamina propria, resulting in button ulcers, and the bacteria can migrate via the portal vein to the liver, causing paratyphoid nodules^{3,10}.

Some conference participants interpreted multinucleated giant cell macrophages in the Peyer's patches as syncytial cells, which can be found feline parvovirus, a primary differential for this case. Also known as feline panleukopenia virus, feline parvovirus, like all parvoviruses, lack polymerase enzymes and are dependent on host cell DNA polymerase II, which are produced during S and early G2 phases, for replication. The resultant effects of parvovirus infection are thus greatest in tissues with a high mitotic rate, such as hematopoietic cells and dividing cells of intestinal crypts¹⁰.

Another differential is *Francisella tularensis*, the causative agent for tularemia. Tularemia, a gram negative intracellular coccobacillus, is passed by several types of ticks and causes necrosis of the liver, spleen, lymph nodes, lung, and bone marrow due to thrombosis, or less commonly caseating granulomas or hemorrhagic enteritis with ulceration over Peyer's patches in cats¹.

Contributor: Adrian W Philbey
Division of Pathological Sciences
Institute of Comparative Medicine
University of Glasgow Veterinary School
Glasgow G61 1QH, Scotland, United Kingdom
<http://www.gla.ac.uk/faculties/vet>

References:

1. Cullen JM, Brown DL. Hepatobiliary system and exocrine pancreas. In: Zachary JF, McGavin MD, eds. *Pathologic Basis of Veterinary Disease*. 5th ed. St. Louis, MO: Elsevier; 2012:432-3.
 2. Daoust PY, Busby DG, Ferns L, Goltz J, McBurney S, Poppe C, Whitney H. Salmonellosis in songbirds in the Canadian Atlantic provinces during winter-summer 1997-98. *Can Vet J* 41(1): 54-59, 2000
 3. Gelberg HB. Alimentary system and the peritoneum, omentum, mesentery, and peritoneal cavity. In: Zachary JF, McGavin MD, eds. *Pathologic Basis of Veterinary Disease*. 5th ed. St. Louis, MO: Elsevier; 2012:357, 376-7.
 4. Pennycott TW, Park A, Mather HA. Isolation of different serovars of *Salmonella enterica* from wild birds in Great Britain between 1995 and 2003. *Vet Rec* 158(24): 817-820, 2006
 5. Rabsch W, Andrews HL, Kingsley RA, Prager R, Tschape H, Adams LG, Baumler AJ. *Salmonella enterica* serotype Typhimurium and its host-adapted variants. *Infect Immun* 70(5): 2249-2255, 2002
 6. Stiver SL, Frazier KS, Mauel MJ, Styer EL. Septicemic salmonellosis in two cats fed a raw-meat diet. *J Am Anim Hosp Assoc* 39(6): 538-542, 2003
 7. Spain CV, Scarlett JM, Wade SE, McDonough P. Prevalence of enteric zoonotic agents in cats less than 1 year old in central New York State. *J Vet Intern Med* 15(1): 33-38, 2001
 8. Tauni MA, Osterlund A. Outbreak of *Salmonella typhimurium* in cats and humans associated with infection in wild birds. *J Small Anim Pract* 41(8): 339-341, 2000
 9. Van Immerseel F, Pasmans F, De Buck J, Rychlik I, Hradecka H, Collard J-M, Wildemaue C, Heyndrickx M, Ducatelle R, Haesebrouck F. Cats as a risk for transmission of antimicrobial drug-resistant *Salmonella*. *Emerg Infect Dis* 10(12): 2169-2174, 2004
 10. Zachary JF. Mechanisms of microbial infections. In: Zachary JF, McGavin MD, eds. *Pathologic Basis of Veterinary Disease*. 5th ed. St. Louis, MO: Elsevier; 2012:169-70, 204-6.
-

CASE II: 3263-07 (JPC 3065887).

Signalment: 7-year-old, neutered, male, cat (*Felis domesticus*).

History: The animal presented with tachypnea and staggering one hour prior to death.

Gross Pathology: Brain: The animal had blood around the mouth and nostrils. The lung lobes had multiple, sometimes extensive, red to pink, often firm foci, and the cut surfaces exuded bloody froth. The right atrium contained a 14.5 cm slender nematode, which was identified upon microscopic examination as *Dirofilaria immitis*. The heart weighed 17.15g and was within normal limits for size and shape.

Contributor's Histopathologic Description: There is severe villous intimal proliferation involving large and medium diameter arteries, which is near-occlusive in some instances. Slender and broad villous-like projections, consisting of stalks of collagen covered by prominent endothelial cells, extend into the lumens of affected arteries. Eosinophils in small to large numbers are dispersed singly or in loose aggregates, accompanied by lesser numbers of macrophages throughout the expanded tunica intima and are also present in the tunica adventitia and in adjacent alveolar septae. There is mild to moderate hypertrophy and hyperplasia of smooth muscle of the tunica media of some arteries in the section, with cytoplasmic vacuolation of few myofibers. In some sections of the large arteries, there are deposits of deeply eosinophilic, beaded material, considered to be necrotic remnants of nematodes, which are surrounded by macrophages and multinucleate giant cells. There is diffuse interstitial congestion, focal hemorrhages, patchy alveolar edema, hyperplasia of bronchial submucosal glands, and smooth muscle hypertrophy and hyperplasia of terminal bronchioles and alveolar ducts.

Contributor's Morphologic Diagnosis: Lung: Endarteritis, proliferative and eosinophilic, diffuse, chronic, severe, with medial hypertrophy and hyperplasia, hemorrhage, edema, smooth muscle hyperplasia and hyperplasia of the bronchial submucosal glands.

Heart: Nematode, intraluminal in right atrium, identified as *Dirofilaria immitis*.

Contributor's Comment: The histologic lesions in the pulmonary arteries are consistent with the endarteritis reported in feline dirofilariasis caused by *Dirofilaria immitis* (heartworm), which is characterized by villous proliferation of the intima together with medial hypertrophy and hyperplasia.⁹

Two representative samples of the lung tissue were submitted. In one section, there is marked proliferative endarteritis together with granulomatous inflammation consisting of a thin layer of macrophages and multinucleate giant cells surrounding the deeply eosinophilic beaded to granular remnants of the parasite. Remnants of the parasite are noted in the adventitia of an affected vessel in the other section.

The marked villous endarteritis in dirofilariasis is reportedly attributable to the presence of live worms in the affected arteries and is of diagnostic importance.² In some cases of dirofilariasis, proliferation of intima results in occlusion of pulmonary arteries.¹ A characteristic lesion of canine dirofilariasis is medial hypertrophy of pulmonary arteries, which can be observed in cats, and has been considered a result of *D.immitis*-mediated stimulation of medial smooth muscle.⁹ In cats, medial hypertrophy is often associated with *Aelurostrongylus abstrusus* and *Toxocara cati* infections^{7,11,12}, which can confound interpretation of these changes caused by *Dirofilaria* infections.¹³ Heartworm (HW) disease is primarily a pulmonary vascular disease caused by the filarial organism, *Dirofilaria immitis*. Mosquitoes, e.g. *Aedes* spp., *Anopheles* spp., and *Culex* spp. are the obligate hosts of the first, second and early third stages of *D. immitis*. These mosquitoes can transmit heartworms to numerous wild and companion animal species. The infective stage of the parasite develops within the malpighian tubules of the mosquito in 13 days, after which time it migrates to the proboscis or cephalic spaces of head and escapes into the new host when the mosquito feeds. The L3 larvae molt to L4s in 2-3 days. They remain in subcutaneous tissue for about 60 days, after which develop into L5 larvae. At the L5 stage, larvae migrate to the pulmonary arteries (predilection site). Microfilariae are produced about 6-7 months post-infection by gravid females. If *D. immitis* develops to maturity in hosts other than dogs, microfilaraemia is generally low or absent.⁸ Both natural and experimental infections have shown that cats are considerably less susceptible to heartworm disease than dogs.¹³ The infective stage (L3) of the parasite when experimentally inoculated into cats caused disease in only 25% of animals, whereas about 44-90% dogs were infected. The prepatent period too was found to be longer, e.g. 8 months or longer, in cats compared to 6 months in dogs.^{5,13}

D.immitis occurs in the right ventricles or pulmonary vessels. Right-sided heart failure secondary to pulmonary hypertension is uncommon in cats.⁴ Most often in cats, cases have a brief history of dyspnea followed by sudden death. These are the result of thromboembolism or acute right-side cardiopulmonary failure.⁹ The pulmonary arterial change in heartworm disease of cats can be more severe than that observed in dogs. Eosinophilia appear to be more common in cats.^{3,13}

Heartworm is enzootic in dogs in the United States.¹⁰ On the other hand, heartworm disease of cats is rare and is mostly detected at the time of necropsy.¹³ Diagnosis of heartworm disease in cats can be difficult because of the transient nature of infection and the low numbers of microfilariae seen in circulation^{5,13}, as well as shorter lifespan of the adult worm in the cat.^{5,13} Angiography and serology have been used to detect heartworm infections, especially in cats due to low levels of microfilaraemia.⁶ ELISA is commonly employed for measurement of anti-*D.immitis* antibody to adult worms.⁶

JPC Diagnosis: Lung, arteries and arterioles: Endarteritis, villar and eosinophilic, diffuse, severe, with mild smooth muscle hyperplasia and Splendore-Hoeppli material.

Conference Comment: The contributor provided an excellent overview of feline pulmonary dirofilariasis. Domestic felids, ferrets, and California sea lions are dead-end hosts, and are not a source of transmission due to the absence of microfilaraemia⁸.

There was some slide variation, and eosinophilic granulomas with Splendore-Hoeppli material were present in some sections. Conference participants felt this was the origin of the deeply eosinophilic conglomerations present in some sections. Other considerations were necrotic nematode debris, as suggested by the contributor, or conglomerations of fibrin and hemoglobin. Conference participants also noticed the presence of hemosiderosis, and attributed this to heart failure.

Contributor: Radhakrishna Sura, Akinyi Nyaoke, Joan Smyth, Richard French, Salvatore Frasca Jr., Herbert Van Kruiningen
University of Connecticut
Department of Pathobiology and Veterinary Science
61 N. Eagleville Road, U-3089
Storrs, CT 06269
<http://www.patho.uconn.edu>

References:

1. Abbott PK: Feline dirofilariasis in Papula. *Aust Vet J* **42**: 247-249, 1966
2. Adcock JL: Pulmonary arterial lesions in canine dirofilariasis. *Am J Vet Res* **22**: 655-662, 1961
3. Calvert CA, Mandell CP: Diagnosis and management of feline heartworm disease. *J Am Vet Med Assoc* **180**: 550-552, 1982
4. Dillon R: Feline dirofilariasis. *Vet Clin North Am Small Anim Pract* **14**: 1185-1199, 1984
5. Donahoe JM: Experimental infection of cats with *Dirofilaria immitis*. *J Parasitol* **61**: 599-605, 1975
6. Green BJ, Lord PF, Grieve RB: Occult feline *Dirofilaria immitis* confirmed by angiography and serology. *J Am Anim Hosp Assoc* **19**: 847-854, 1982
7. Hamilton JM: Pulmonary arterial disease of the cat. *J Comp Pathol* **76**: 133-145, 1966
8. Maxie MG, Robinson WF. Cardiovascular system. In: Maxie MG, ed. *Jubb, Kennedy, and Palmer's Pathology of Domestic Animals*. 5th ed., vol. 3, Philadelphia, PA: Elsevier Saunders; 2007:87-9.
9. McCracken MD, Patton S: Pulmonary arterial changes in feline dirofilariasis. *Vet Pathol* **30**: 64-69, 1993
10. Patton S, McCracken MD: Prevalence of *Dirofilaria immitis* in cats and dogs in eastern Tennessee. *J Vet Diagn Invest* **3**: 79-80, 1991
11. Swerczek TW, Nielsen SW, Helmboldt CF: Ascariasis causing pulmonary arterial hyperplasia in cats. *Res Vet Sci* **11**: 103-104, 1970
12. Van Vleet JF, Ferrans VJ: Cardiovascular system, Arterial Diseases, and growth disturbances. In: Thompson's Special Veterinary Pathology, eds. Thomson RG pp. 333. B.C. Decker, Philadelphia, PA, 1988
13. Wong MM, Pedersen NC, Cullen J: *Dirofilaria immitis* in Cats. *J Am Anim Hosp Assoc* **19**: 855-864, 1982

CASE III: 09L-0417 (JPC 3133673).

Signalment: 7 year old, male, English bull terrier, *Canis lupus familiaris*, canine.

History: The animal was submitted for post mortem examination after being found dead. Poisoning was suspected.

Gross Pathology: Necropsy was performed approximately 20 hours after estimated time of death. The animal was moderately obese, weighing 37.9 kg. Both kidneys were diffusely pale, showing a dry cut surface with white multifocal pinpoint subcapsular and cortical areas. Both parathyroids were moderately enlarged. The ribs and skull exhibited moderate demineralisation. A moderate left cardiac concentric hypertrophy was observed. In the left adrenal gland, severe cortical compression atrophy due to a medullary, pale cream soft mass was seen. Age-related changes, consisting of mild bilateral nodular endocardosis of atrio-ventricular valves, moderate erosive coxarthrosis and mild nodular hepatic and prostatic hyperplasia were present.

Contributor's Histopathologic Description: Kidneys: Glomeruli are variably-sized and mostly hypocellular containing a high amount of eosinophilic, acellular and amorphous material (amyloid, Congo/Sirius red positive) and exhibit mesangial atrophy. Under UV light, the amyloid, in the Congo red stained sections, shows orange fluorescence (as described by Linke).⁸ Congophilia is lost in sections pretreated with potassium permanganate confirming the amyloid to be of secondary origin. Amyloid is also seen in renal tubules, within the lumen of a pelvic artery (amyloid cast), and in the renal pelvis. Glomeruli also contain to lesser extent deposition of fibrous tissue and diffusely moderate to severely thickened Bowman capsules (Masson's Trichrome stain positive). Mild to moderate, multifocal lymphoplasmacytic infiltration (variable within provided slides) and tubular mineralization (calcification) are present. Renal tubules often contain protein casts.

Arteries/arterioles: Moderate to severe deposition of amyloid and fibrosis are also seen in the intima and media of arteries and arterioles in the liver, left ventricle and septum.

Left adrenal gland: Adrenal medulla is densely cellular with cells arranged in packets and nests and supported by a moderately fine fibrovascular stroma that occasionally thickens and dissects the parenchyma, leading to a disarranged lobular pattern. The mass is composed of round to polygonal cells exhibiting mild to moderate anisocytosis and anisokaryosis. The cytoplasm of neoplastic cells is finely granular, eosinophilic and most often poorly demarcated. Nuclei are round to oval, hyperchromatic, with finely stippled chromatin and most frequently, no nucleoli. Mitotic figures are rare. Neoplastic cells are synaptophysin positive (neuroendocrine origin) and are found intravascularly within adjacent mesentery and extending directly from the adrenal gland into an adjacent large artery (phrenicoabdominal artery?), subcapsularly and supracapsularly (infiltrative growth pattern). Scattered binucleated cells, haemosiderophages and cytomegaly are observed. Occasional vascular degeneration with mineralization (calcification) is seen in the adrenal cortex. Due to the medullary mass, a moderate to severe, diffuse cortical atrophy is present. Transition between adrenal medulla and cortex is multifocally poorly demarcated and in scattered areas a rim of fibrous tissue separates the two regions (pseudocapsule formation).

Contributor's Morphologic Diagnosis: 1- Kidney, severe diffuse glomerular, intratubular and pelvic amyloidosis, mild to moderate diffuse glomerulosclerosis and interstitial lymphoplasmacytic nephritis with focal calcification
 2-Kidney, liver and heart, moderate to severe multifocal amyloid angiopathy and arterio/arteriolosclerosis
 3-Adrenal, malignant pheochromocytoma with consecutive moderate to severe diffuse adrenal cortical atrophy,

Contributor's Comment: Amyloidosis consists of extracellular deposition of protein fibrils in beta-pleated sheets which are resistant to proteolytic cleavage and insoluble. The most frequent secondary changes associated with its presence include pressure atrophy, chronic renal failure and hepatic rupture. Secondary amyloidosis occurs when there is a long term rise in acute phase proteins, to be more precise in serum amyloid A, seen in chronic inflammation or neoplasia.^{10,11,20} Studies have indicated its value as a prognostic marker for tumours and existence of metastases, in both humans^{4,15} and animals.²⁰ Some authors attribute a tumourigenesis role to SAA based on the fact that different binding sites to extracellular matrix (ECM) components have been found in its structure.¹⁰ The ECM provides tecdular structure, controls cell binding and so they propose that SAA possibly interacts with the ECM in a way that inhibits cellular adhesion and so promotes metastases.¹⁰ In human medicine, it has been observed to coexist frequently with neuroendocrine tumours.²¹ In humans, amyloid precursor like protein 1 has been reported to be more frequently expressed in neuroendocrine tumours of the small intestine.¹ In the latter studies it was also observed that in intestinal carcinomas, amyloid precursor proteins co-localised with synaptophysin, leading to the hypothesis that they would be transported to the cell membrane by synaptic microvesicles and affect tumour cell adhesion and invasiveness.¹ It has also been described that epinephrine increases the release of acute phase proteins⁷. Amyloid deposition is most commonly seen in the spleen, liver, enteric mucosa and arterial walls.^{5,12} The following table shows the main types of amyloid found in animals:

Type of amyloid	Aetiology	Structures or organs mostly affected	Species and breeds most frequently affected
Primary (AL) or Immunoglobulin derived - Localized or generalized	Immunoglobulin λ or κ in plasma cells dyscrasias from B cell monoclonal proliferation 25 types identified	Spleen, heart, tongue, Kidneys, nerves and joints (atypical distribution)	Uncommon Most frequent in dogs, horses and cats
Secondary or reactive systemic amyloidosis	AA (amyloid associated) serum protein (an acute phase reactant and the major HDL apolipoprotein) produced by hepatocytes after cytokine stimuli (mainly IL6) ^{5,10}	Kidneys, arteries, spleen, liver, enteric mucosa, joints (gallinae)	Dogs, cattle, horses and cats Less frequently: swine and goats
Familial		Peripheral nerves, kidneys, heart, liver	<u>Cats:</u> Abyssinian, Siamese, Oriental <u>Dogs:</u> Beagles, Sharpei, Gray

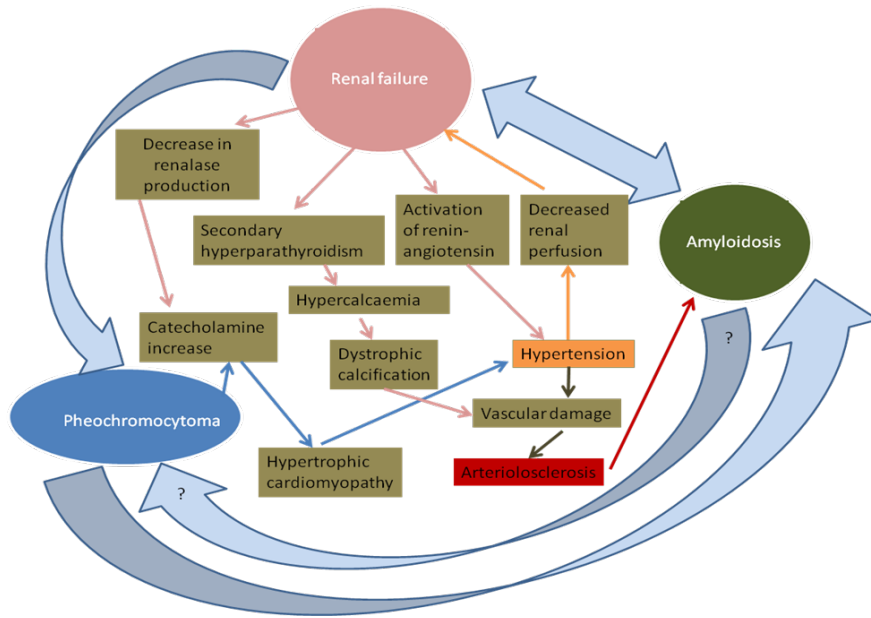
			collies, English foxhound. <u>Cattle:</u> Holstein (with bovine leukocyte adhesion deficiency)
Apolipoprotein A1 derived	Apolipoprotein A1	Pulmonary arteries	Dogs
Islet amyloid polypeptide derived amyloid	Islet amyloid polypeptide Non-insulin dependent	Pancreas	Cats

Pheochromocytomas are tumours of chromaffin cells and are the most frequent tumours observed in the adrenal medulla.² Even though chromaffin cells produce catecholamines (epi/norepinephrine), in animals, clinical signs from their overproduction are rarely observed with a pheochromocytoma. When present, these symptoms consist mostly in tachycardia, cardiac hypertrophy and arterial sclerosis. In the rat, epinephrine has also been referred to act as a stimulant of interleukin release and secondary acute phase reactant.⁷ Pheochromocytoma pathogenesis is unclear and has been associated in rats with chronic progressive glomerulopathy.^{2,14,16} Genetic factors, pituitary tumours, hyperthyroidism, autonomic nervous system stimulation, hypercalcaemia, vitamin D₃ and diets rich in calcium, retinoids or sugars have also been implicated.^{2,14,16,23} Interaction between the kidney and the adrenal gland include reninase, which is produced in the glomeruli and proximal tubules and induces metabolisation of catecholamines, and thus lead to a decrease in the blood pressure.^{3,7,19} There is a reduction in reninase synthesis in uraemic and end stage renal disease patients.^{3,8,19} The reninase gene is also expressed in the heart, skeletal muscle and liver.⁸ In animals, hypertension is most commonly of secondary nature and associated with chronic renal failure. However, the reverse can happen, where renal changes can also be due to reduction in renal perfusion secondary to hypertension.¹³

Arteriosclerosis includes various pressure-induced vascular changes and can be either mainly hyaline or hypertrophic. In the uraemic dog, the arterial and arteriolar lesions consist of deposition of subendothelial fibrin, internal elastic lamina dystrophy, necrosis of smooth muscle, mineralization and occasionally neutrophilic infiltration.¹³ All of these changes were seen in this case together with the amyloid angiopathy, leading to the hypothesis that together with glomerulosclerosis, arteriosclerosis was a more predominant feature that worsened and no longer is presented as blatant lesions.

Secondary hyperparathyroidism is seen in chronic renal failure and leads to osseous resorption in an attempt to increase the calcium levels. This mechanism changes the Ca:Ph ratio and as a consequence dystrophic calcification occurs.

The conditions seen in this case and their severity and distribution suggest that they are aetiologically related. Below, based on the above provided information, a hypothetical graphical simplifying attempt of the relationship between the present conditions is provided.



- JPC Diagnosis:**
1. Adrenal gland: Malignant pheochromocytoma.
 2. Kidney: Amyloid, glomerular, segmental to global, diffuse, moderate, with multifocal lymphoplasmacytic interstitial nephritis.
 3. Heart, mural arteries: Arteriosclerosis, hyaline, multifocal, mild (hyalinosis), with cardiac myofiber loss and fibrosis.

Conference Comment: The contributor provided an excellent description of amyloidosis, and our comment will only elaborate on some other details of this important pathologic condition in animal species.

Primary amyloidosis is rare in animals and may be encountered in the horse in the nasal vestibule and rostral parts of the nasal septum and turbinates. Secondary amyloidosis is far more common due to a reactive change caused by the synthesis of serum amyloid A (SAA) in the liver in response to IL-1, IL-6, and TNF in chronic inflammation. Cheetahs and Siberian tigers develop renal medullary interstitial amyloidosis in response to gastritis. Familial amyloidosis is usually autosomal recessive, and autosomal dominant in Abyssinian cats, which along with the Chinese Shar Pei develop amyloid in the kidneys, and Siamese cats develop amyloid in the liver. Localized amyloidosis can be deposited in the pancreas of cats and non-human primates with type II diabetes mellitus. Chickens can develop amyloid arthropathy associated with *Enterococcus faecalis*, and common sites of amyloid in geese and swans are the spleen and kidneys. In dogs, *Hepatozoon americanum* and *Ehrlichia canis* have been associated with renal amyloidosis and glomerulopathy, and excess dietary vitamin A has been associated with renal amyloidosis in cats^{12,13,19,20,22}.

Renal amyloidosis may be presumptively diagnosed from a urine protein:creatinine of greater than 18. A ratio of less than 0.5 is considered normal, 1-3 indicates tubular disease, and greater than 3 indicates glomerular disease. Ultrastructurally, amyloid appears as non-branching fibrils of 0.7-1.0 μm diameter that form single to laterally-aggregated bundles or interlocking mesh-like ribbons that lack periodicity⁶.

A differential diagnosis for the mural thickening of coronary arteries in this case is hyalinosis, a relatively common finding in the older dog. Hypertrophic hyalinization (hyalinosis) generally occurs in the intramural coronary and small meningeal and cerebral arteries of old dogs. There is generally no clinical significance in the CNS lesions, but this may result in multifocal intramural myocardial infarction. If valvular endocardiosis is present, these two lesions may lead to congestive heart failure. The mural deposits are most often fibrin or glycosaminoglycans (GAGs). Amyloid, as seen in this case¹³ is far less common in hyalinosis.

Vascular invasion in the adrenal gland was not present on all slides.

Contributor: Rita Pereira/Udo Hetzel
Department of Veterinary Pathology
Veterinary Science Building
University of Liverpool
Crown Street
Liverpool
L69 7ZJ
United Kingdom

References:

1. Arvidsson Y, Andersson E, Bergstrom A, Andersson MK, Altiparmak G, Illerskog AC, Ahlman H, Lamazhapova D, Nilsson O: Amyloid precursor-like protein 1 is differentially upregulated in neuroendocrine tumours of the gastrointestinal tract. *Endocr Relat Cancer* **15**: 569-581, 2008
2. Capen C: Endocrine glands. *In: Pathology of Domestic Animals*, ed. MG M, pp. 419-422. Saunders Elsevier, 2007
3. Desir GV: Renalase deficiency in chronic kidney disease, and its contribution to hypertension and cardiovascular disease. *Curr Opin Nephrol Hypertens* **17**: 181-185, 2008
4. Findeisen P, Zapatka M, Peccerella T, Matzk H, Neumaier M, Schadendorf D, Ugurel S: Serum amyloid A as a prognostic marker in melanoma identified by proteomic profiling. *J Clin Oncol* **27**: 2199-2208, 2009
5. Gruys E: Protein folding pathology in domestic animals. *J Zhejiang Univ Sci* **5**: 1226-1238, 2004
24. Gueft B, Ghidoni JJ. The Site of Formation and Ultrastructure of Amyloid. *Am J Pathol*. 1963 November; 43(5): 837-854.
6. Kahl M, Schade R: Catecholaminergic modulation of rat acute phase reactants. *Agents Actions* **32**: 98-99, 1991
7. Li G, Xu J, Wang P, Velazquez H, Li Y, Wu Y, Desir GV: Catecholamines regulate the activity, secretion, and synthesis of renalase. *Circulation* **117**: 1277-1282, 2008
8. Linke RP: Highly sensitive diagnosis of amyloid and various amyloid syndromes using Congo red fluorescence. *Virchows Arch* **436**: 439-448, 2000
9. Malle E, Sodin-Semrl S, Kovacevic A: Serum amyloid A: an acute-phase protein involved in tumour pathogenesis. *Cell Mol Life Sci* **66**: 9-26, 2009
10. Maxie MG NS: Urinary system. *In: Pathology of Domestic Animals*, ed. MG M, 5th edition ed., pp. 463-465. Saunders Elsevier, 2007
11. Maxie MN, SJ: Urinary system. *In: Pathology of Domestic Animals*, ed. MG M, 5th edition ed., pp. 463-465. Saunders Elsevier, 2007
12. Maxie MR, WF: Cardiovascular system. *In: Pathology of Domestic Animals*, ed. MG M, 5th edition ed., pp. 59-60. Saunders Elsevier, 2007
13. Newman SJ. The urinary system. *In: Zachary JF, McGavin MD, eds. Pathologic Basis of Veterinary Disease*. St. Louis, MO: Elsevier; 2012:627-628,640.
14. Nyska A, Haseman JK, Hailey JR, Smetana S, Maronpot RR: The association between severe nephropathy and pheochromocytoma in the male F344 rat -- the National Toxicology Program experience. *Toxicol Pathol* **27**: 456-462, 1999
15. Ramankulov A, Lein M, Johannsen M, Schrader M, Miller K, Loening SA, Jung K: Serum amyloid A as indicator of distant metastases but not as early tumor marker in patients with renal cell carcinoma. *Cancer Lett* **269**: 85-92, 2008
16. Rosol TJ, Yarrington JT, Latendresse J, Capen CC: Adrenal gland: structure, function, and mechanisms of toxicity. *Toxicol Pathol* **29**: 41-48, 2001
17. Schiffrin EL, Lipman ML, Mann JF: Chronic kidney disease: effects on the cardiovascular system. *Circulation* **116**: 85-97, 2007
18. Snyder PW. Diseases of immunity. *In: Zachary JF, McGavin MD, eds. Pathologic Basis of Veterinary Disease*. St. Louis, MO: Elsevier; 2012:284-288.
19. Stalker MJ HM: Liver and biliary system. *In: Pathology of Domestic Animals*, ed. MG M, 5th edition ed., pp. 315-316. Saunders Elsevier, 2007
20. Steinhoff MM, Wells SA, Jr., DeSchryver-Keckskemeti K: Stromal amyloid in pheochromocytomas. *Hum Pathol* **23**: 33-36, 1992
21. Tecles F, Caldin M, Zanella A, Membiela F, Tvarijonaviciute A, Subiela SM, Ceron JJ: Serum acute phase protein concentrations in female dogs with mammary tumors. *J Vet Diagn Invest* **21**: 214-219, 2009

22. Terio KA, O'Brien T, Lamberski N, Famula TR, Munson L. Amyloidosis in black-footed cats (*Felis nigripes*). *Vet Pathol.* 2008;43(3):393-400.
23. Tischler AS, Powers JF, Alroy J: Animal models of pheochromocytoma. *Histol Histopathol* **19**: 883-895, 2004
-

CASE IV: V10-1558 (JPC 4001079).

Signalment: Seven-year-old male castrated Siamese cross, feline (*Felis catus*)

History: The cat presented with a mass on the left iris of unknown duration. An aspiration of the iris was diagnosed as a plasmacytoma. Chemotherapy was attempted with no response. The left eye was enucleated and submitted for histopathological diagnosis.

Gross Pathology: There was a 1cm mass expanding the ventral iris.

Laboratory Results: Neoplastic cells are immunohistochemically positive for S-100 and melan-A.

Contributor's Histopathologic Description: Eye (left), anterior uvea: Diffusely expanding the iris, ciliary body, irido-corneal angle, and infiltrating into the adjacent sclera and uvea, and protruding into the anterior chamber is an unencapsulated, highly cellular, poorly demarcated neoplasm arranged in closely packed sheets, streams and bundles, and vague packets separated by a thin fibrovascular stroma. Neoplastic cells exhibit two morphologic forms. The first is a pleomorphic round cell with distinct cell borders, abundant granular eosinophilic to clear cytoplasm, and 1-2 large round to irregular often peripheralized nuclei with coarsely stippled chromatin and 1-3, large, occasionally irregular, magenta nucleoli. Anisocytosis and anisokaryosis is marked. The second form of neoplastic cell consists of spindle cells with indistinct cell borders, a moderate amount of eosinophilic cytoplasm, a round to oval nucleus with fine to coarsely stippled chromatin and 1-2 nucleoli. Anisocytosis and anisokaryosis is moderate. The mitotic rate in both morphologic populations is highly variable and reached up to 8 mitotic figures per high power field. Rarely, melanin pigment is identified within the cytoplasm of neoplastic cells.

Contributor's Morphologic Diagnosis: Eye, iris, left: Melanoma, diffuse, Siamese cross (*Felis catus*), feline.

Contributor's Comment: The cat in this case was interesting in that it presented with a visible, white nodule protruding into the anterior chamber. An aspiration of that mass consisted of multiple individualized round cells with abundant clear to pale blue cytoplasm, and 1-2 small round eccentrically placed nuclei. The mass was initially diagnosed as a potential plasmacytoma with a recommendation for removal and confirmation due to the rarity of that particular type of tumor. There is only a single case report by Michau et.al. in 2003 diagnosing an intraocular extramedullary plasmacytoma in a cat.⁵

The differential diagnosis for the gross presentation included nodular iris melanoma and a uveal cyst. On histopathologic examination, the neoplastic melanocytes diffusely infiltrated iridial stroma, ciliary body, and irido-corneal drainage angle and protruded into the anterior chamber resulting in the grossly visible nodule. Melanocytic tumors are the most common primary intraocular neoplasms in cats,^{2,7} with intraocular sarcomas and ciliary epithelial neoplasms also occurring with lesser frequency.³

Diffuse iris melanoma generally begins as an asymmetrical abnormal pigmentation of the iris that may be clinically noted several years prior to the development of neoplasia.² This area of pigmentation may remain static or progress to nodular iridial irregularities and diffusely infiltrate the sclera, ciliary body, and posterior segment.² Neoplastic cells originate from melanocytes that line the anterior border of the iris.⁹ Rarely, atypical melanomas, not associated with diffuse iris melanoma, may arise multifocally within the limbus or choroid. Little is known about their origin, behavior, and prognosis.^{2,4}

Three morphologically distinct neoplastic cells are often found in feline diffuse iris melanoma. These different morphologic cell types may occur in any combination within diffuse iris melanoma, and no prognostic significance has yet been attached to these various combinations.^{2,9}

- 1) **Pleomorphic round cells** (most common type), consist of cells with abundant eosinophilic cytoplasm and a primarily centralized round nucleus. These cells may occasionally exhibit cytomegaly, cytoplasmic invaginations forming pseudo-inclusions, and variable amounts of pigmentation.
- 2) **Spindle cells** (2nd most common).
- 3) **Balloon cells**, consist of cells with abundant eosinophilic to clear cytoplasm with a high cytoplasm to nuclear ratio and a small often centralized round nucleus. No prognostic significance has been associated with the morphologic type of neoplastic cells.

Poorly differentiated intraocular melanomas may exhibit a wide variety of morphologic and pigmentation characteristics. This often results in a struggle to develop a definitive morphologic diagnosis on H&E alone. Common immunohistochemical stains include HMSA-5, S-100, and tyrosinase.¹

Feline diffuse iris melanomas are considered more likely to metastasize than canine uveal melanomas, but due to the slow progression of the tumor, the overall risk that an animal will die from the melanoma is less than 20%.⁹ In cats, metastasis associated with diffuse iris melanomas has been documented affecting lungs, lymph nodes, skeletal system and abdominal viscera.⁶ Predictors of metastasis include scleral invasion, invasion into posterior iris epithelium, and overall tumor size.⁹

Retroviral antigen has been identified in both intraocular sarcoma and diffuse iris melanoma.^{1,3,8} In a retrospective study by Stiles et. al. in 1999, 3 of 36 intraocular melanomas tested positive for FeLV-FeSV DNA by nested PCR.⁷ Another retrospective study in 2002 by Cullen et al failed to find viral DNA sequences in the intraocular melanomas examined in 10 cats.³

JPC Diagnosis: Eye, ciliary body, iris, choroid: Diffuse melanoma.

Conference Comment: Conference participants discussed the presence of ganglion cell layer and inner nuclear layer atrophy likely due to occlusion of the drainage angle by the neoplasm. Occlusion prohibits adequate drainage resulting in an increase in intraocular pressure (IOP) and subsequent development of closed angle secondary glaucoma^{6,10}. Histologic findings characteristic of glaucoma are cupping of the optic disk (pathognomonic when present), dilated axonal sheaths, and axonal degeneration and loss. Progressive retinal changes include atrophy of the afferent nerve fiber layer and ganglion cell layer resulting in accentuation of Muller cells, thinning of the inner plexiform and nuclear layers and eventual blending together of the inner and outer nuclear layers, with the retina eventually being reduced to a thin glial scar with few outer nuclear layer remnants and melanophages from the retinal pigment epithelium. Diffuse iridal melanomas are the most common cause of secondary glaucoma in cats. Both increased IOP and degenerative structural changes must be present to warrant a diagnosis of glaucoma^{6,10}; however, since IOP was not reported for this cat, and the eye was still visual according to the contributor, the cause of the retinal atrophy can only be speculated.

The contributor mentions uveal cysts, or pigmented uveal nodules, as a gross differential diagnosis. Uveal cysts are fluid-filled cysts which may be congenital or arise secondary to trauma or inflammation. They are non-neoplastic, non-progressive and considered an incidental finding.

Contributor: MAJ Margaret Hanson
Air Force Research Laboratory
2509 Kennedy Circle, Building 125
Brooks City Base, TX 78235

References:

1. Cullen CL, Haines DM, Jackson ML, Grahn BH: Lack of detection of feline leukemia and feline sarcoma viruses in diffuse iris melanomas of cats by immunohistochemistry and polymerase chain reaction. *J Vet Diagn Invest* 14:340-343, 2002
2. Dubielzig RR: Tumors of the eye. In: *Tumors in Domestic Animals*, 4th ed., Meuten DJ, ed., pp. 744-749. Iowa State Press, Ames, IA, 2002
3. Grahn BH, Peiffer RL, Cullen CL, Haines DM: Classification of feline intraocular neoplasms based on morphology, histochemical staining, and immunohistochemical labeling. *Vet Ophthalmol* 9:395-403, 2006

4. Harris BP, Dubielzig RR: Atypical primary ocular melanoma in cats. *Vet Ophthal* 2:121-124, 1999
5. Michau TM, Proulx DR, Rushton SD, Olivry T, Dunston SM, Gilger BC, Davidson MG: Intraocular extramedullary plasmacytoma in a cat. *Vet Ophthalmol* 6:177-181, 2003
6. Njaa BL, Wilcock BP. The eye and ear. In: Zachary JF, McGavin MD, eds. *Pathologic Basis of Veterinary Disease*. 5th ed. St. Louis, MO: Elsevier; 2012:1215-20, 1228-9.
7. Planellas M, Pastor J, Torres MD, Peña T, Leiva M: Unusual presentation of a metastatic uveal melanoma in a cat. *Vet Ophthalmol* 13:391-394, 2010
8. Stiles J, Bienzle D, Render JA, Buyukmihci NC, Johnson EC: Use of nested polymerase chain reaction (PCR) for detection of retroviruses from formalin-fixed, paraffin-embedded uveal melanomas in cats. *Vet Ophthalmol* 2:113-116, 1999
9. Wilcock B, Dubielzig RR, Render JA: Histological Classification of Ocular and Otic Tumors of Domestic Animals. 2nd Series, Vol. IX, pp.18-19, 24-25. Armed Forces Institute of Pathology, Washington, DC, 2002
10. Wilcock, BP. Eye and ear. In: Maxie MG, ed. *Jubb, Kennedy, and Palmer's Pathology of Domestic Animals*. 5th ed., vol. 1, Philadelphia, PA: Elsevier Saunders; 2007:514-5, 538-42.