

2017 Mock Exam Interpretive

Not for dissemination outside of the
JPC

Photo Credits

Veterinary Pathology

Journal of Veterinary
Diagnostic Investigation

Dr. Oscar Quesada

Dr. Gordon Andrews

Dr. Matt Valentine

Dr. Leonardo Minatel

Dr. Laura Polledo

Dr. Arnon Gal

Dr. Martha Delaney

Dr. Guillermo Rimoldi

Dr. Francesco Gianitti

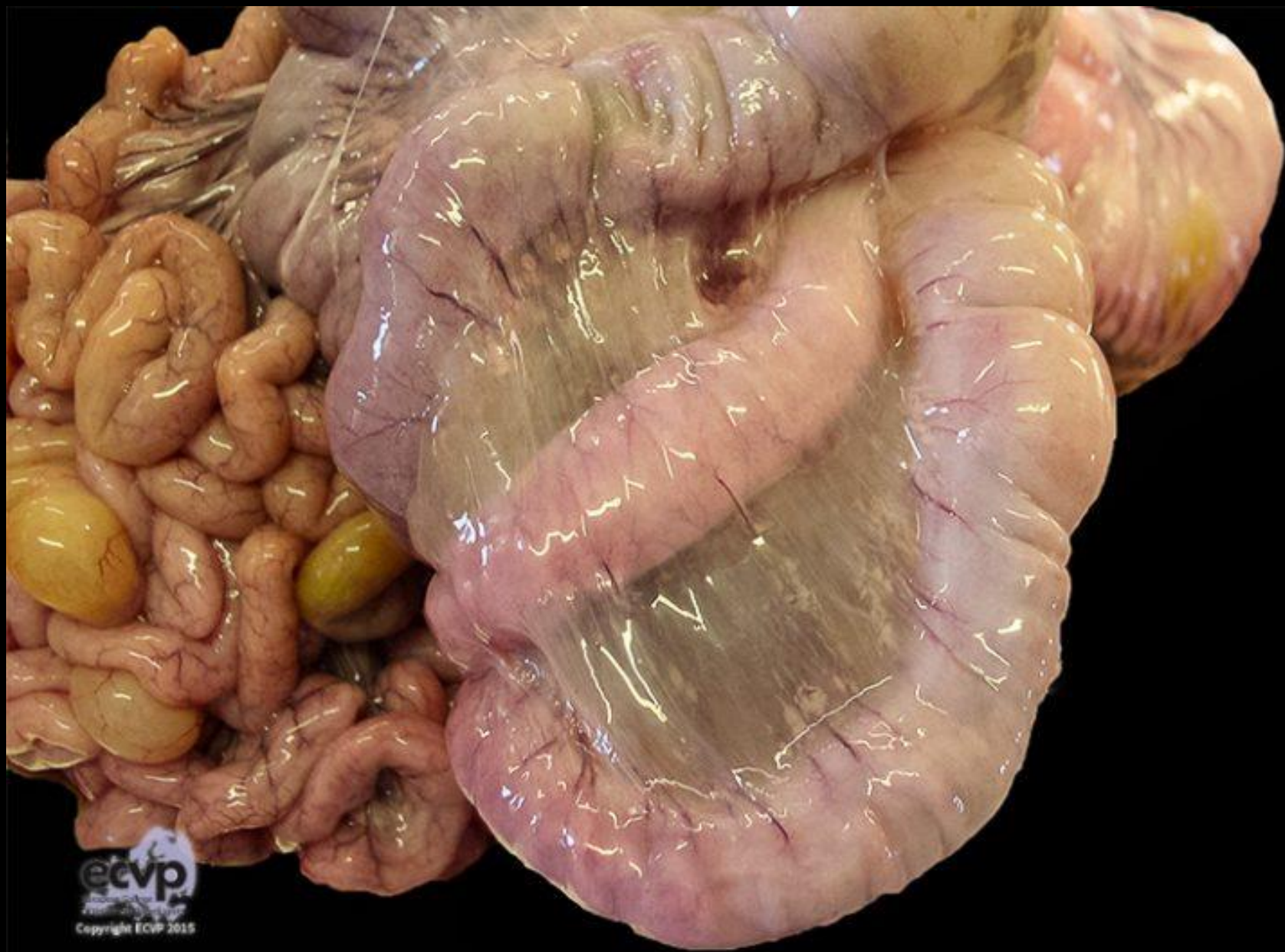Dr. J.A. Garcia

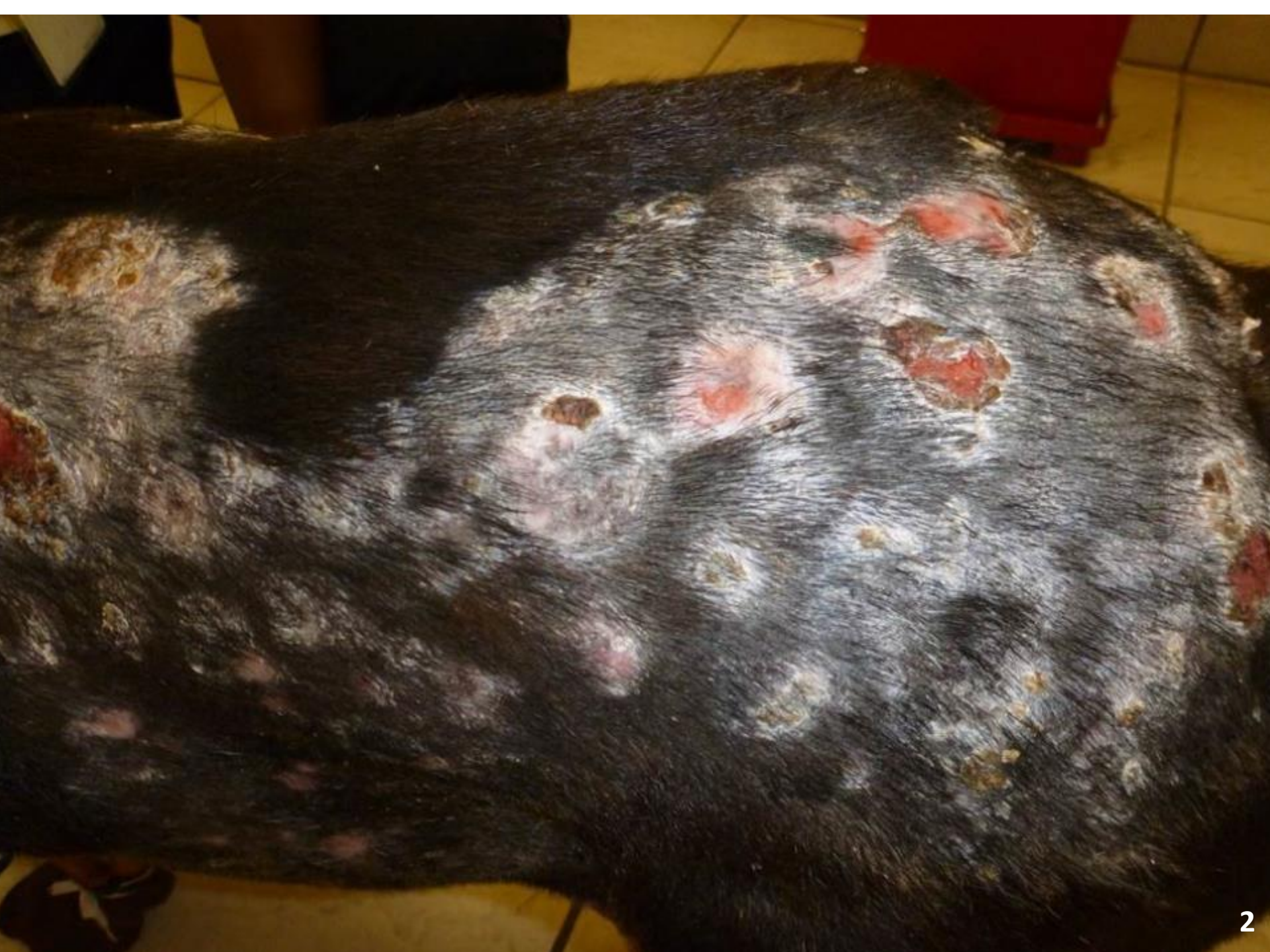Dr. Maria Gimeno

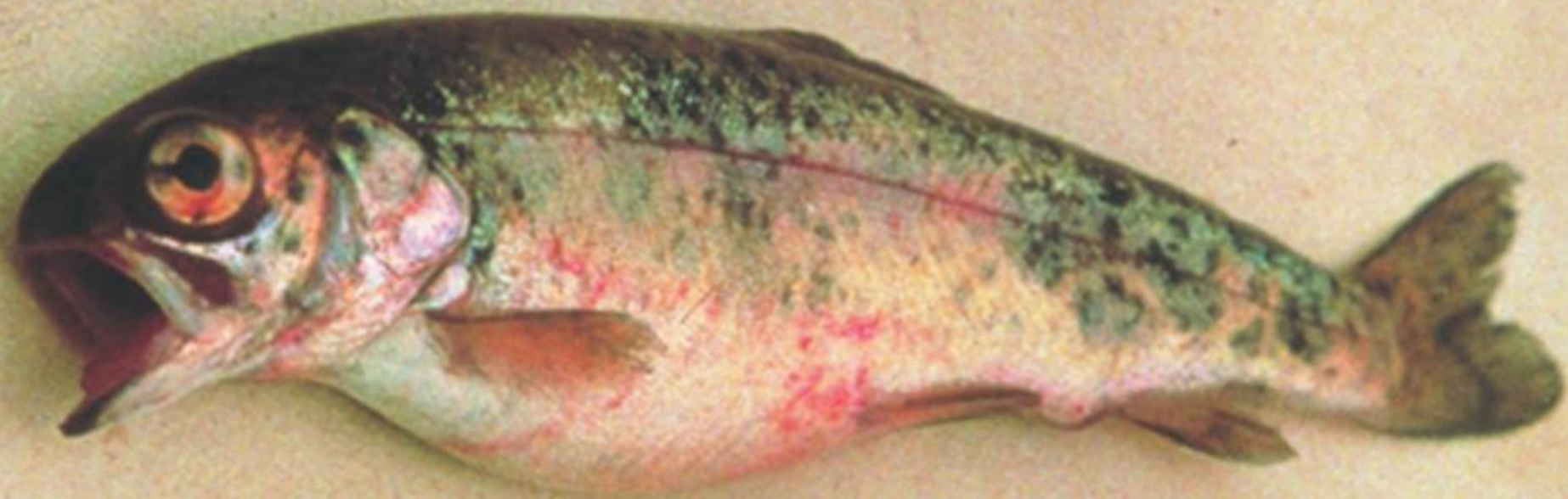Dr. Sarah Hale

Dr. Jennifer Scruggs

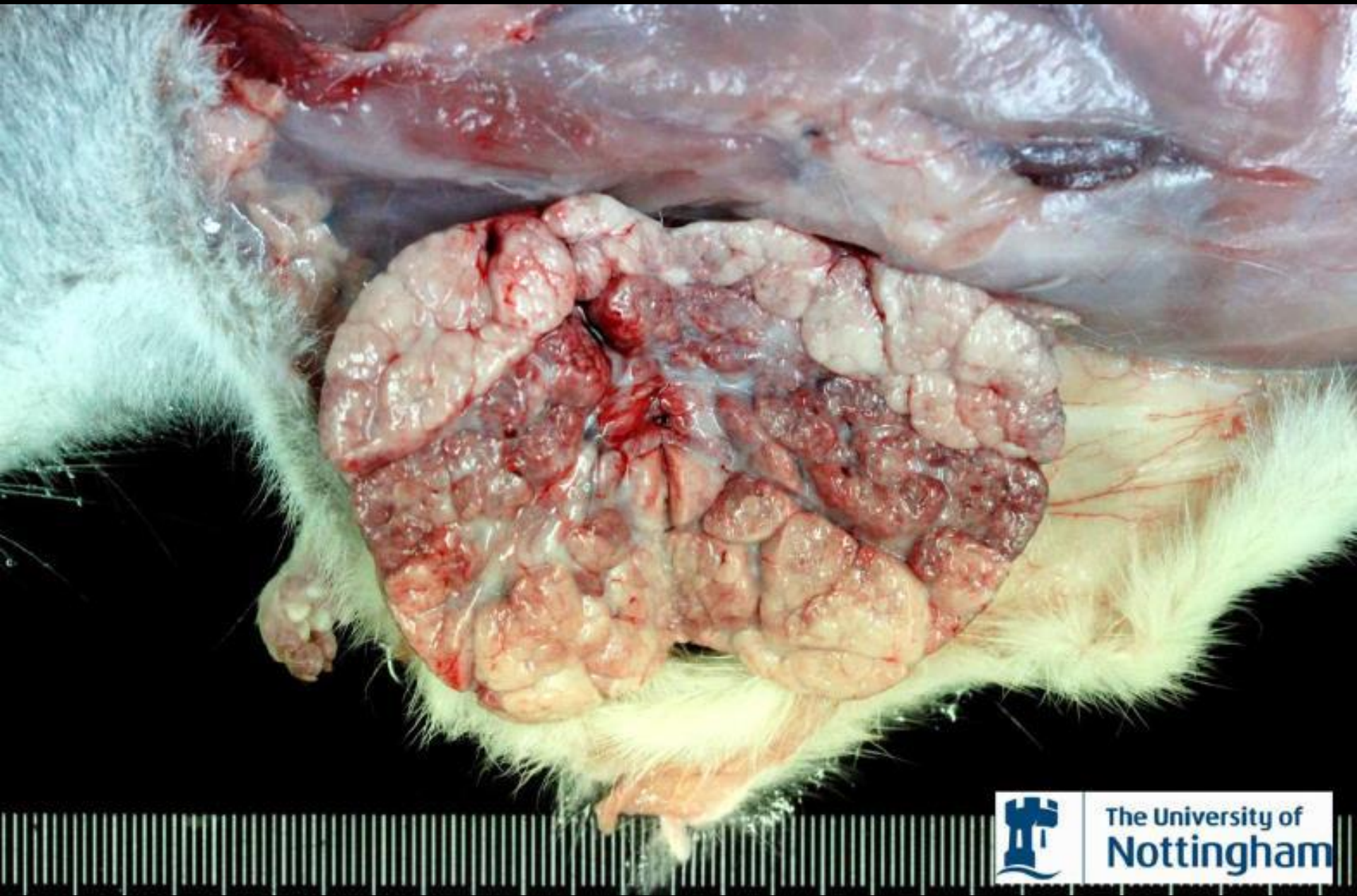
Dr. Jeff Wolff





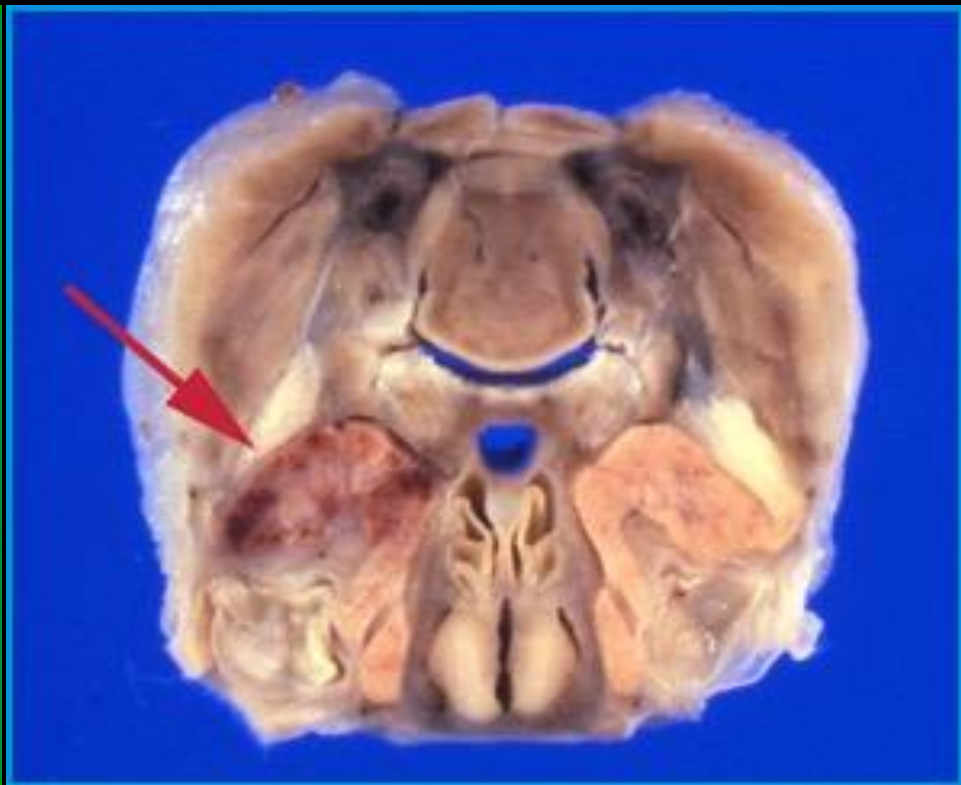
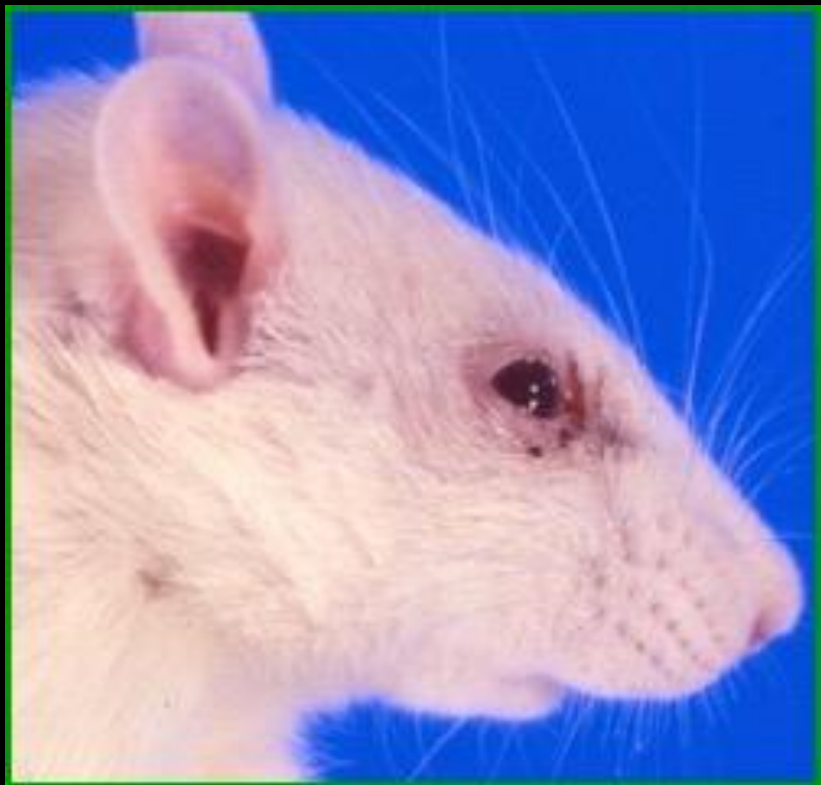

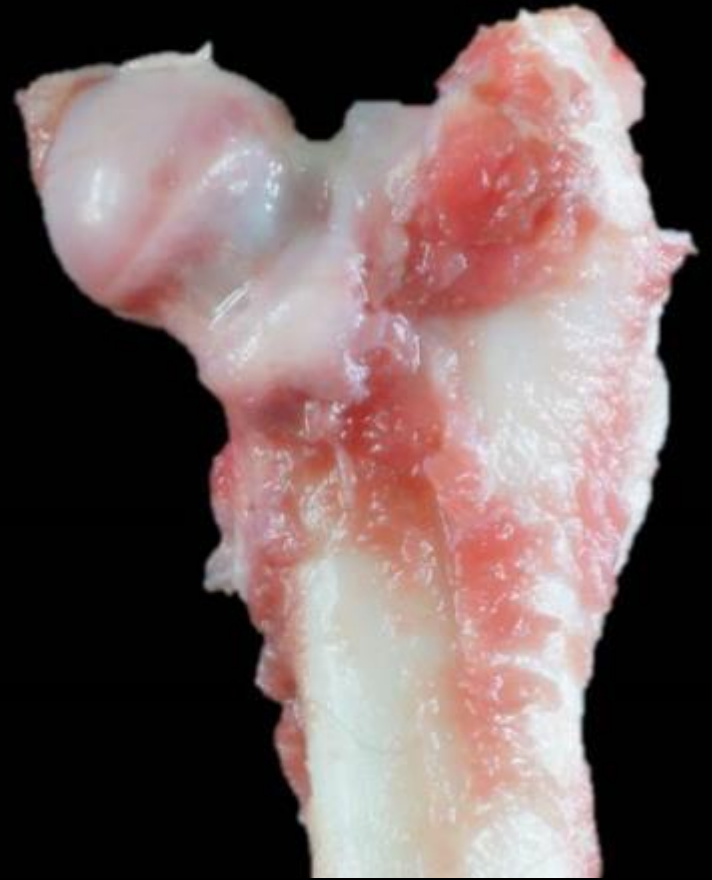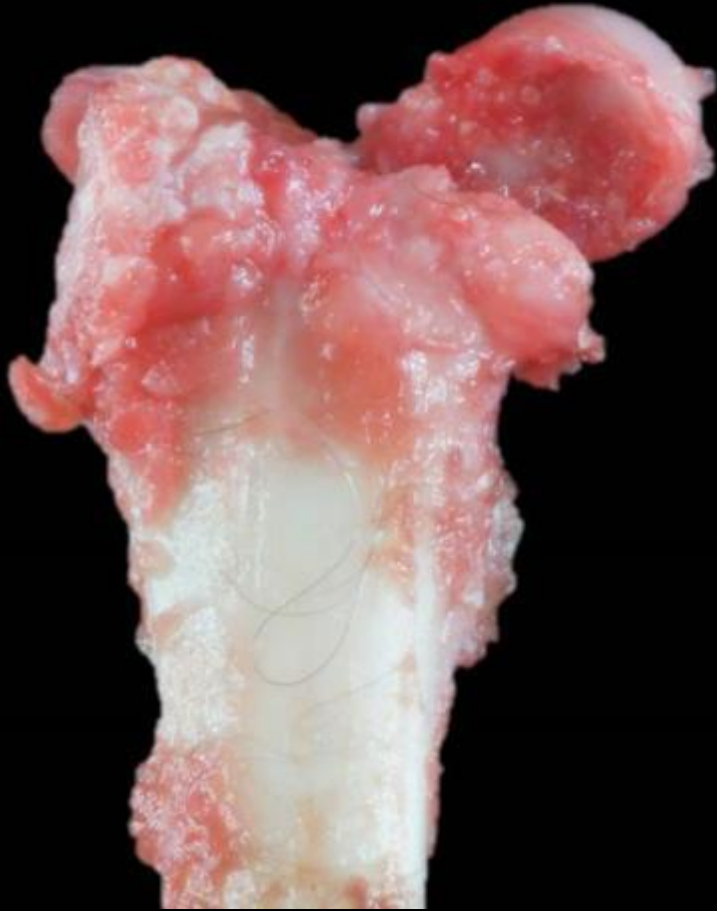Source HJ Schlotfeldt



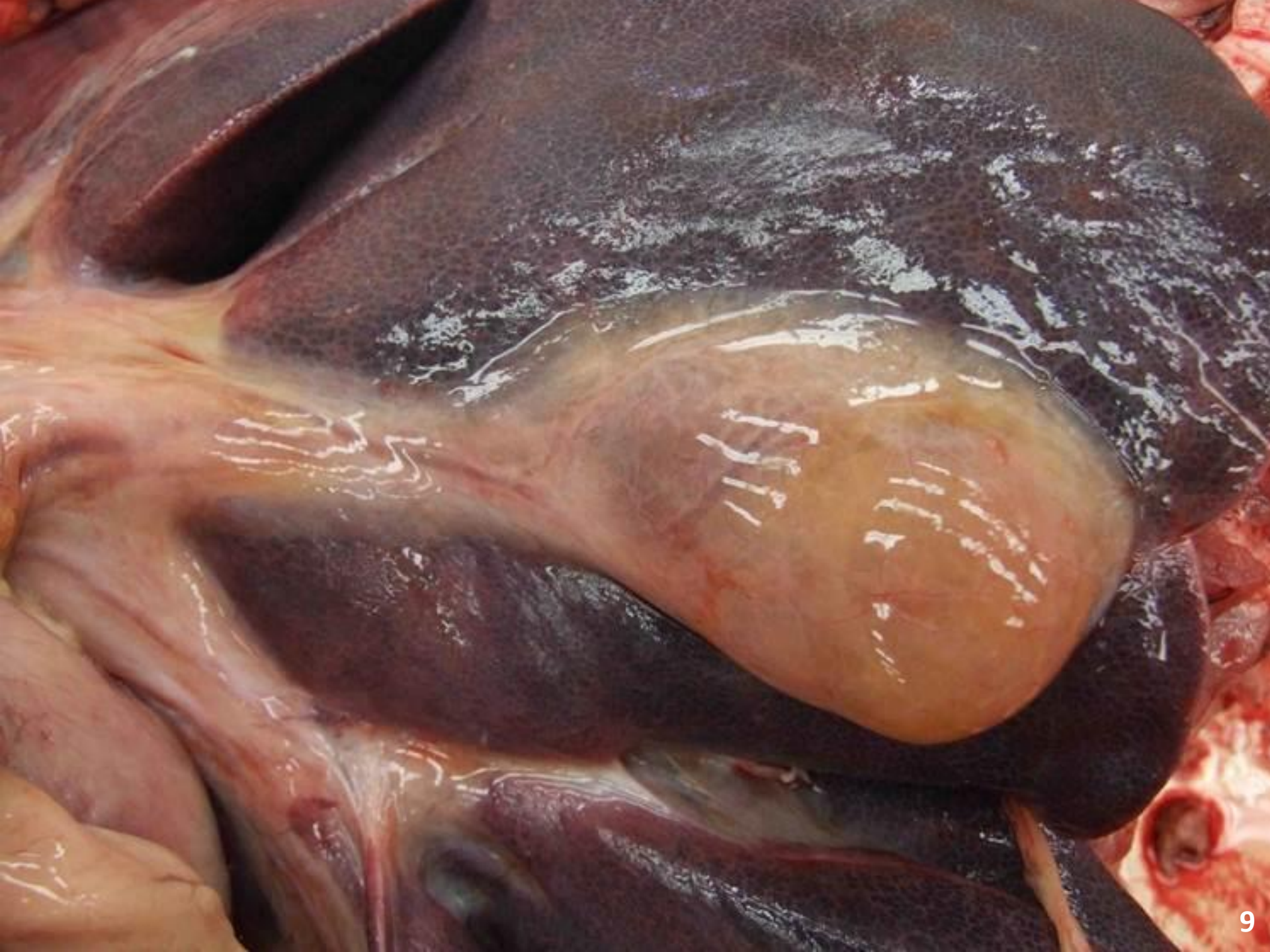The University of
Nottingham

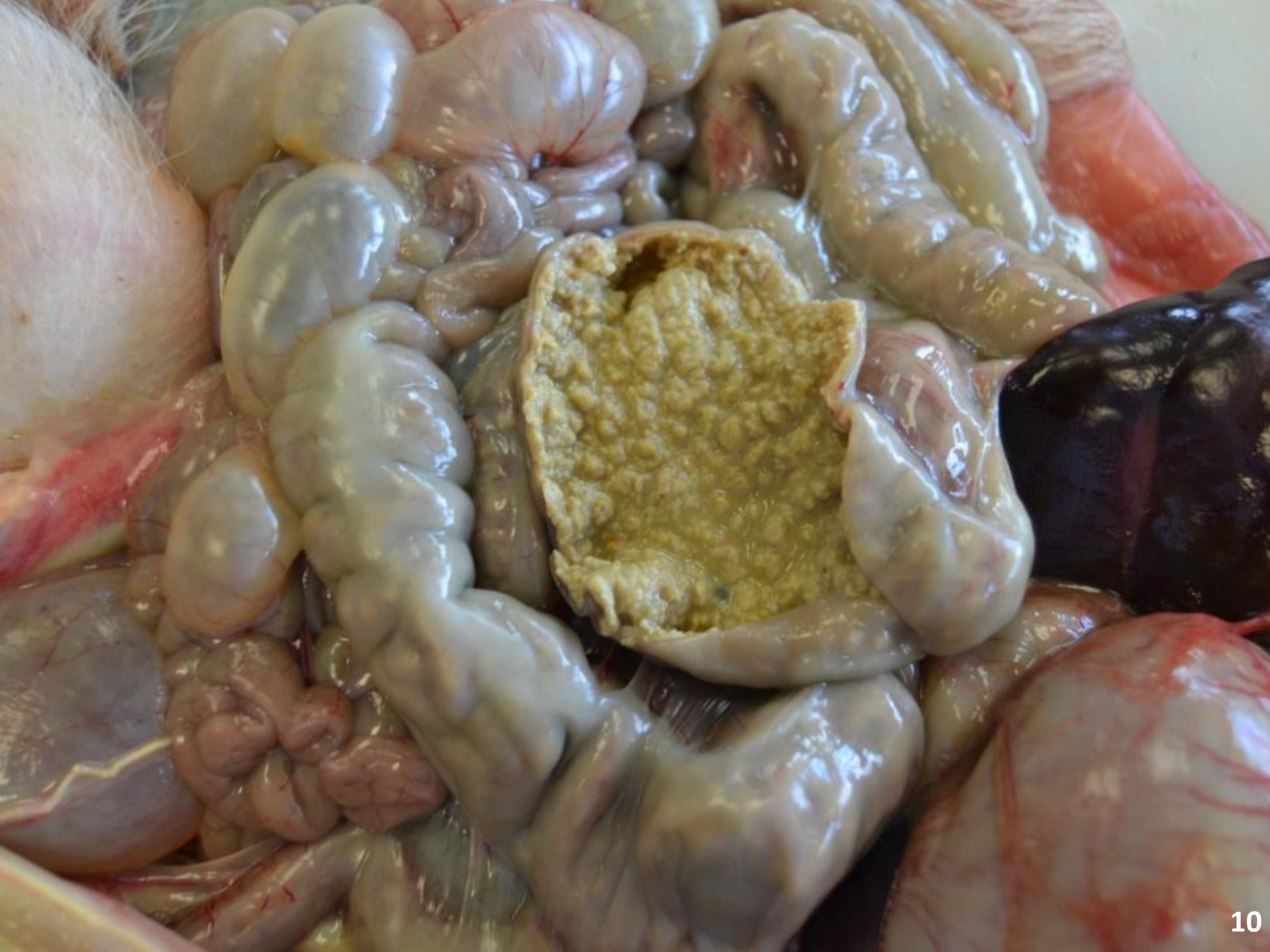


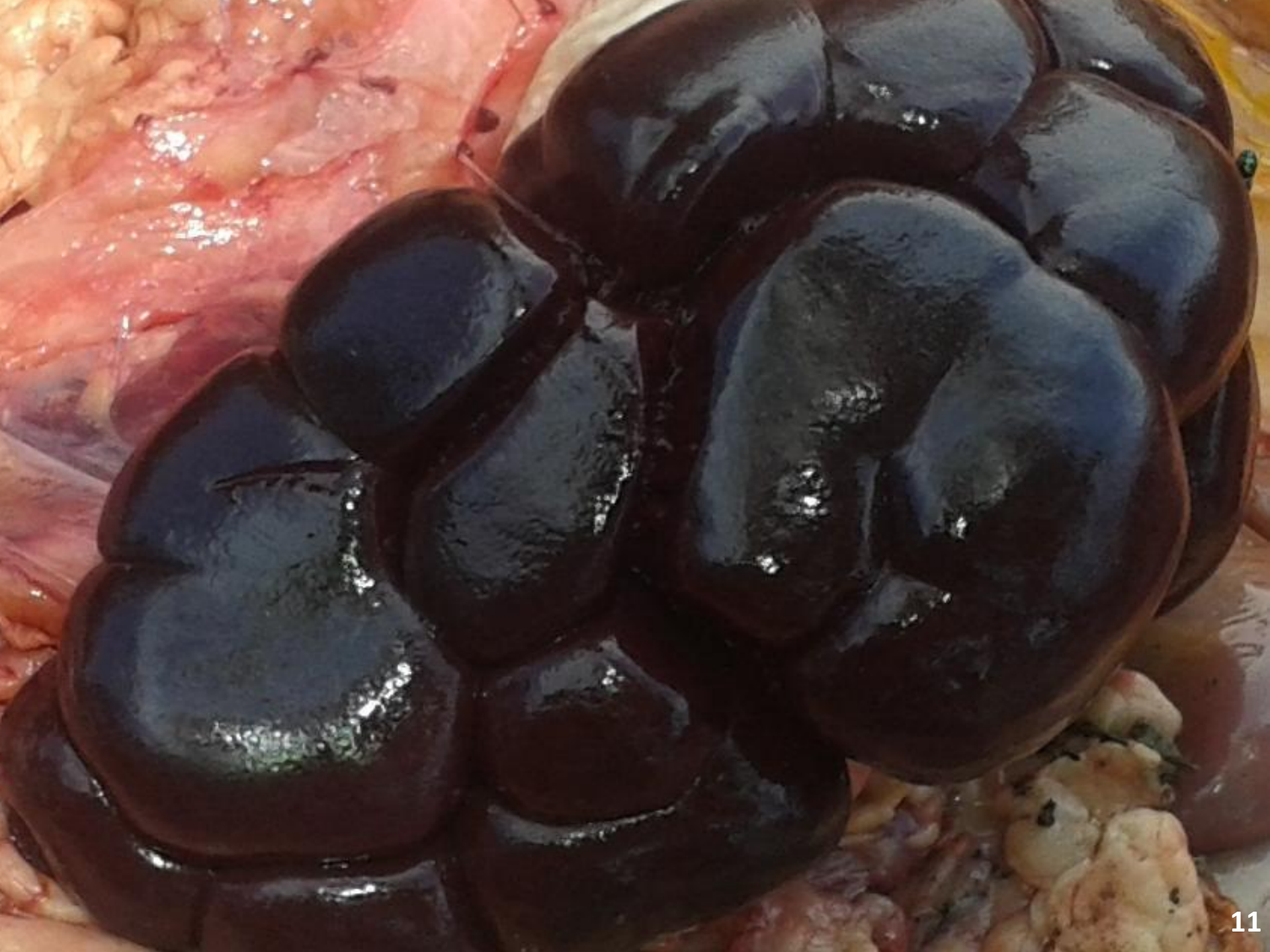
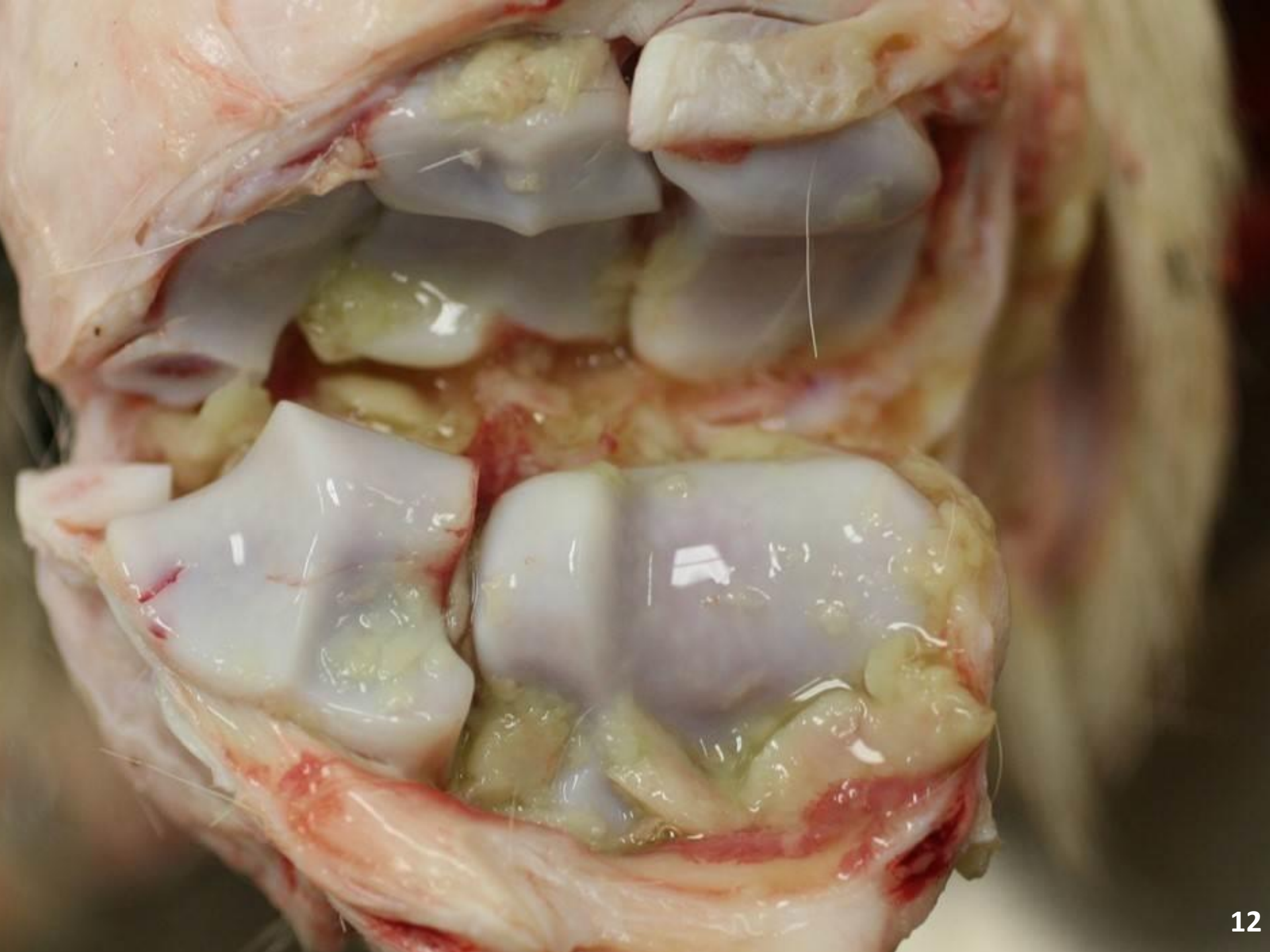




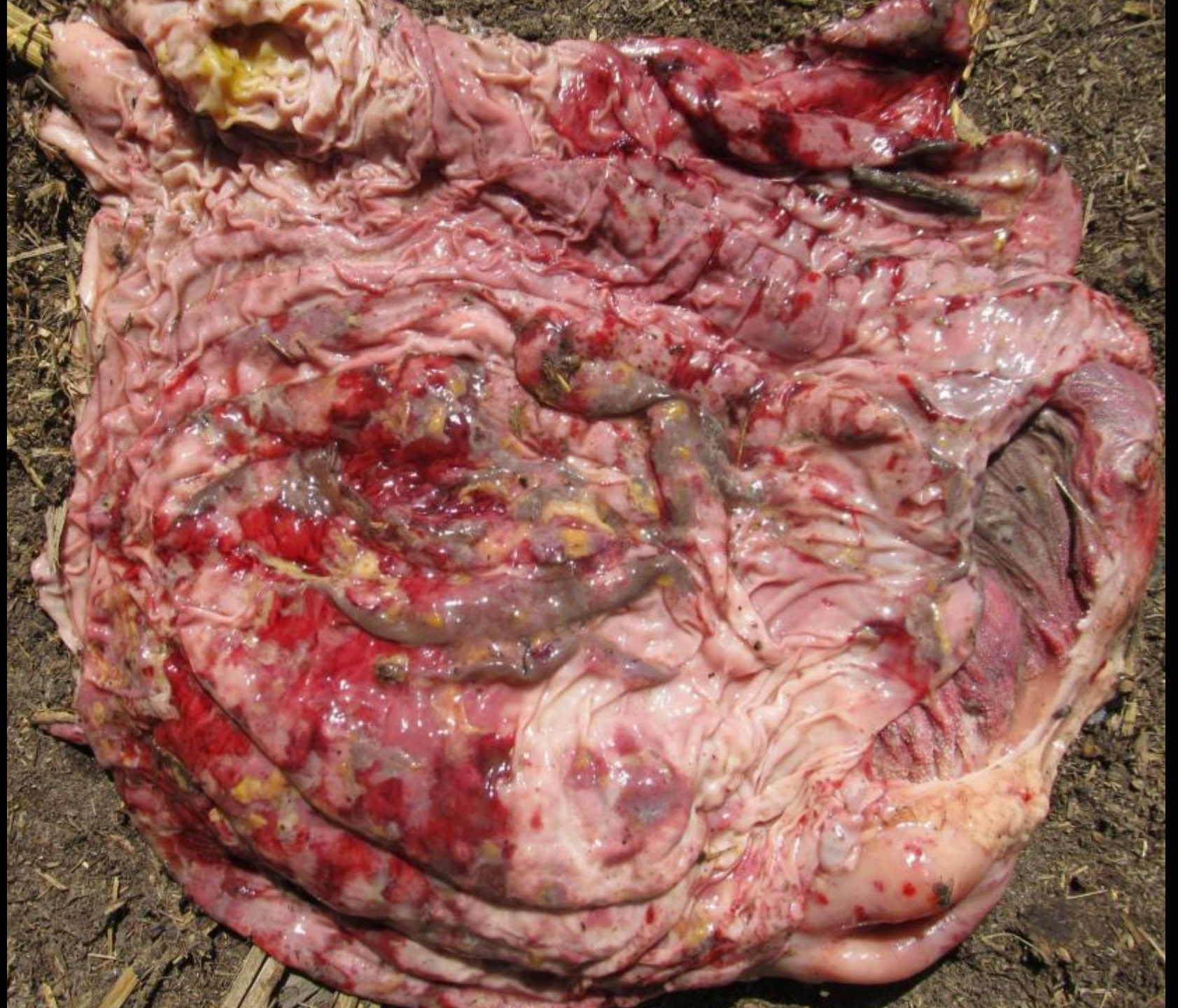


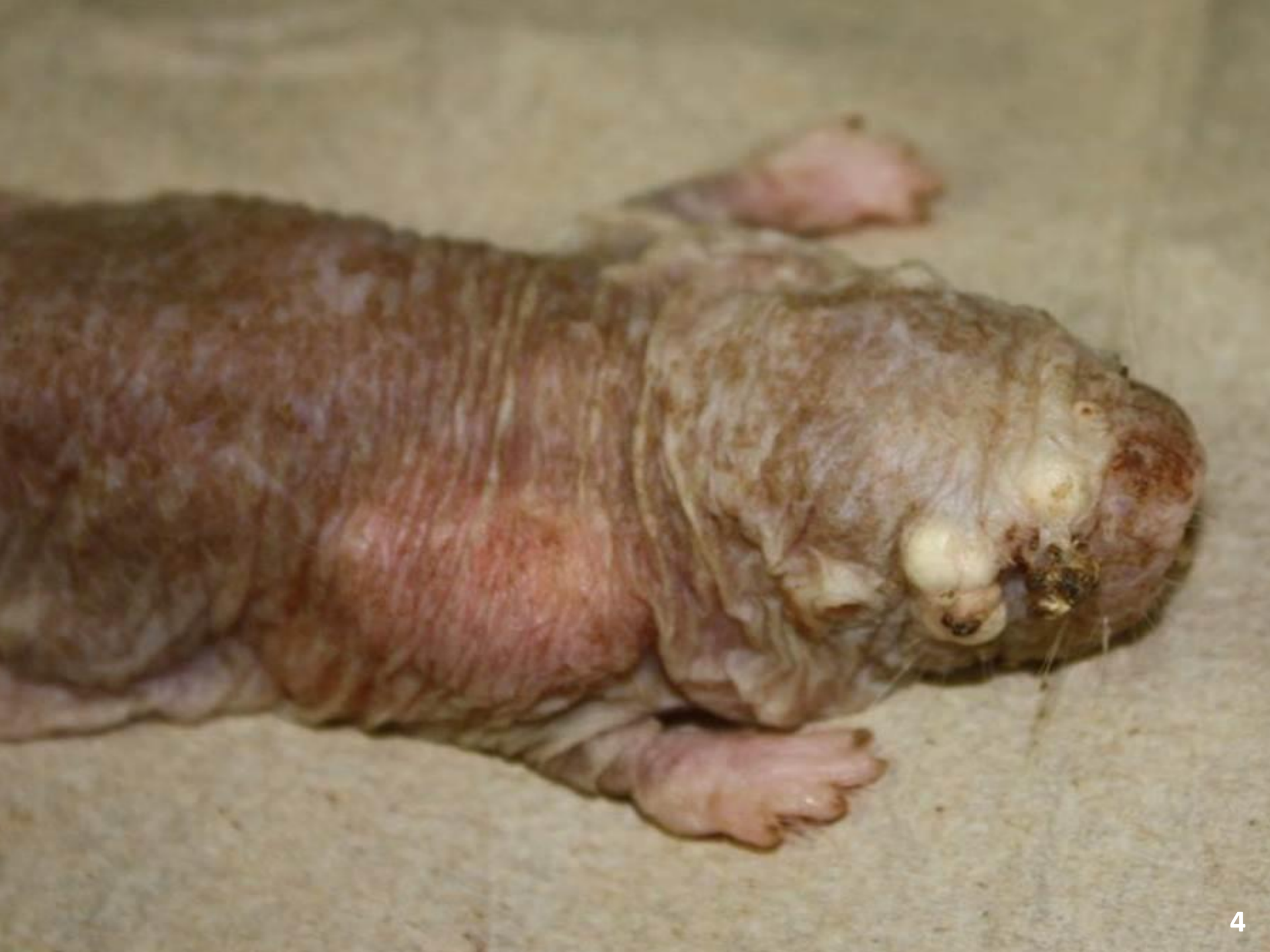


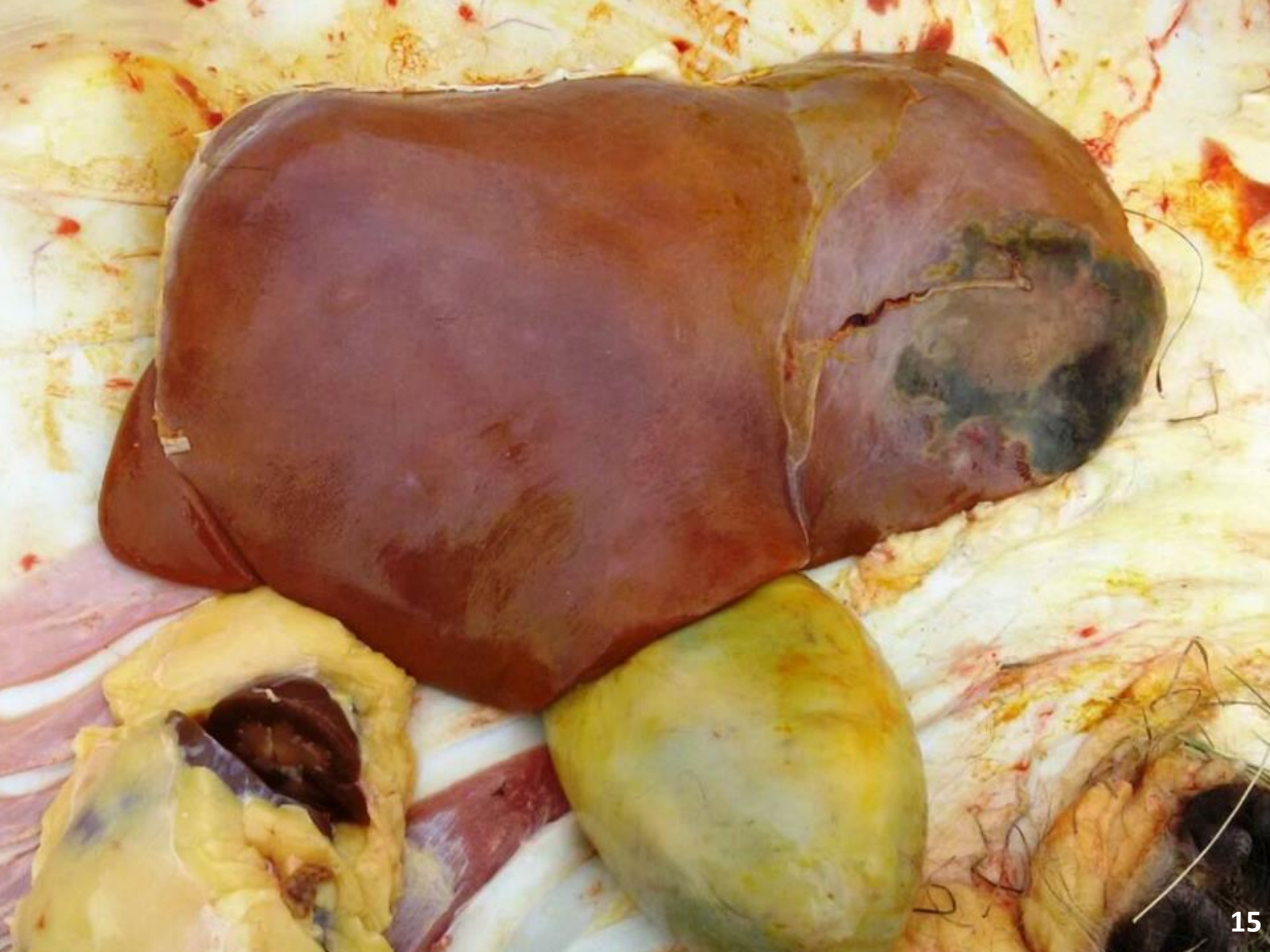


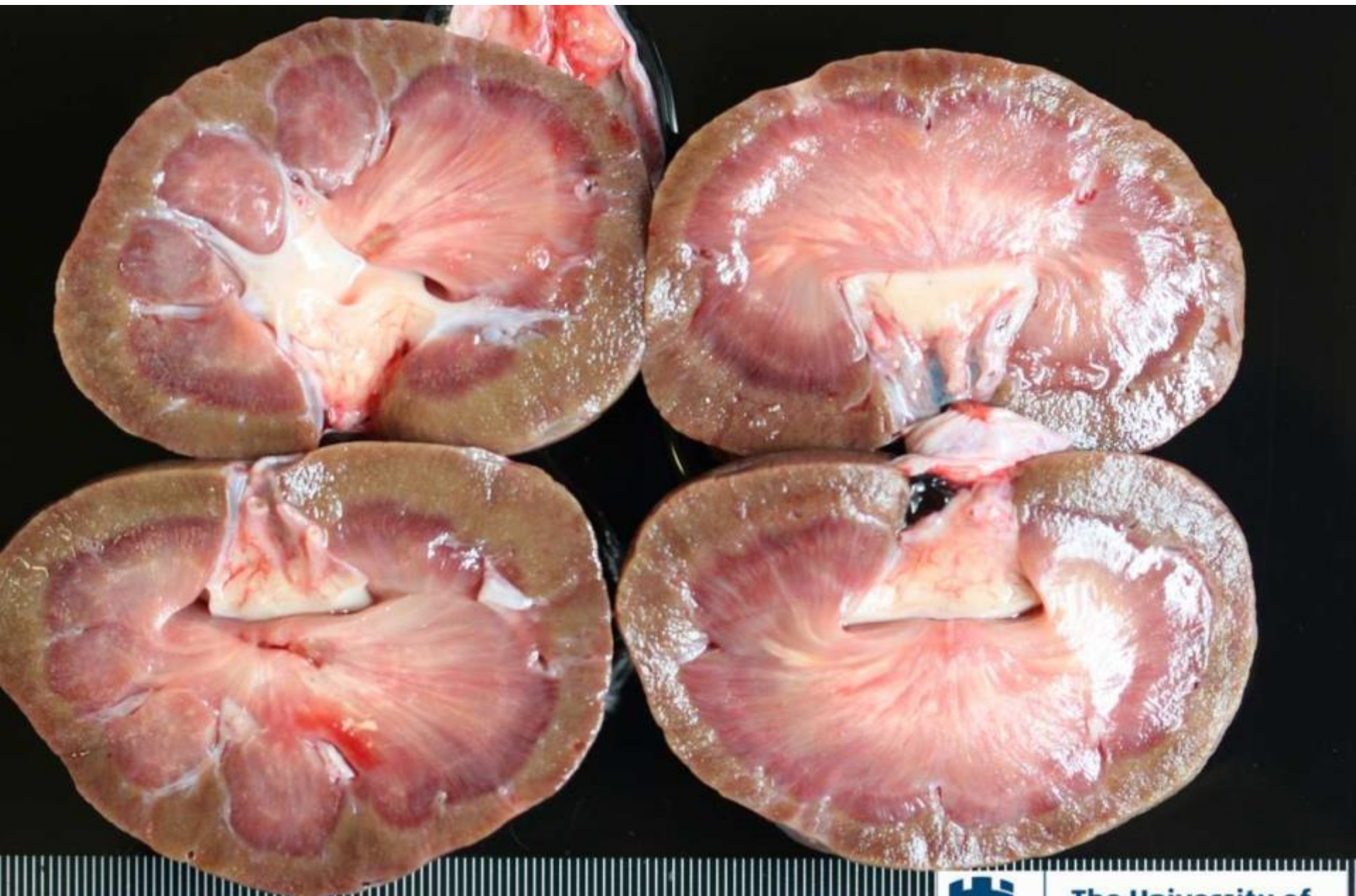






7

8

9

10

11

12

13

14

15

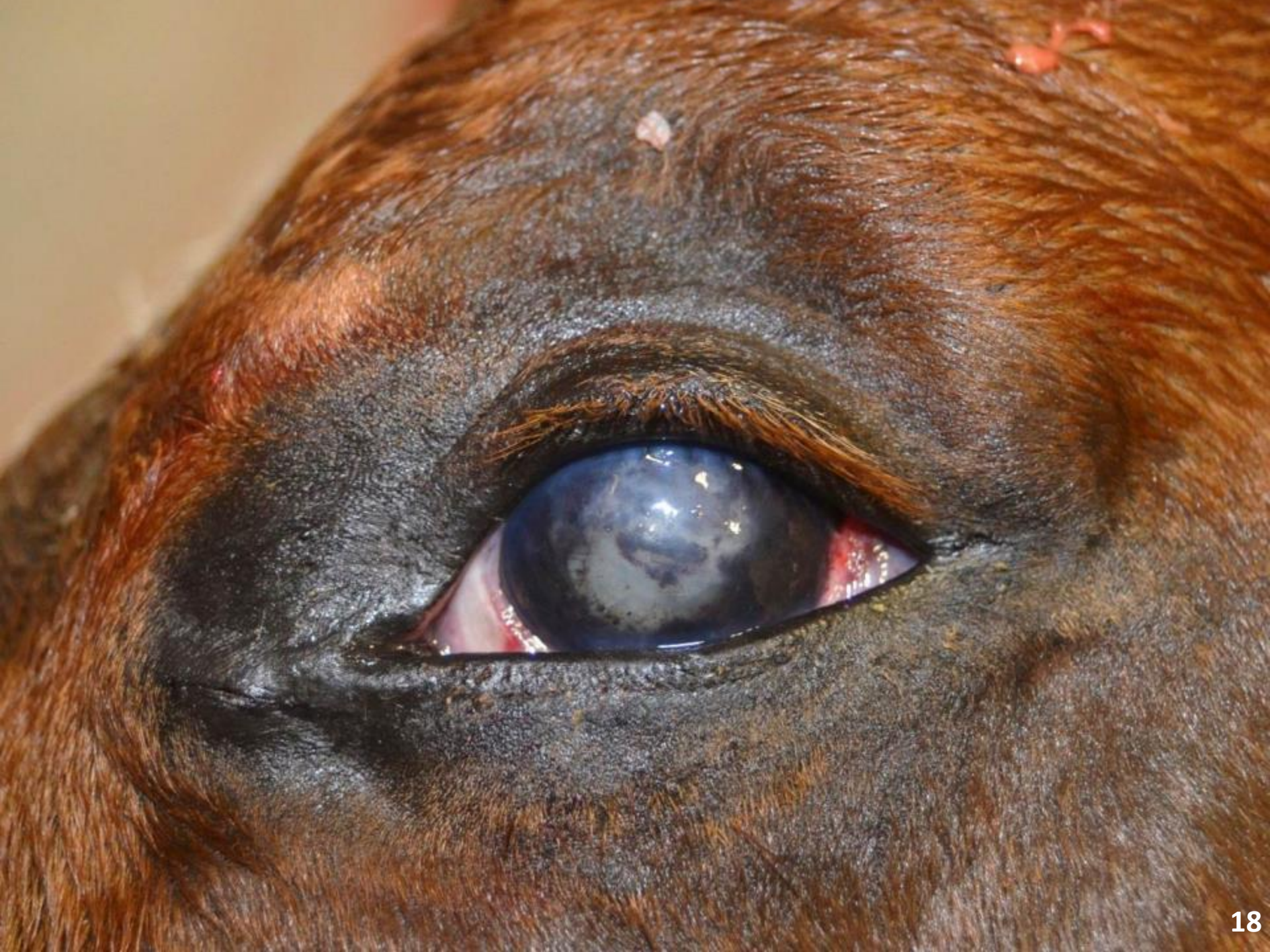16

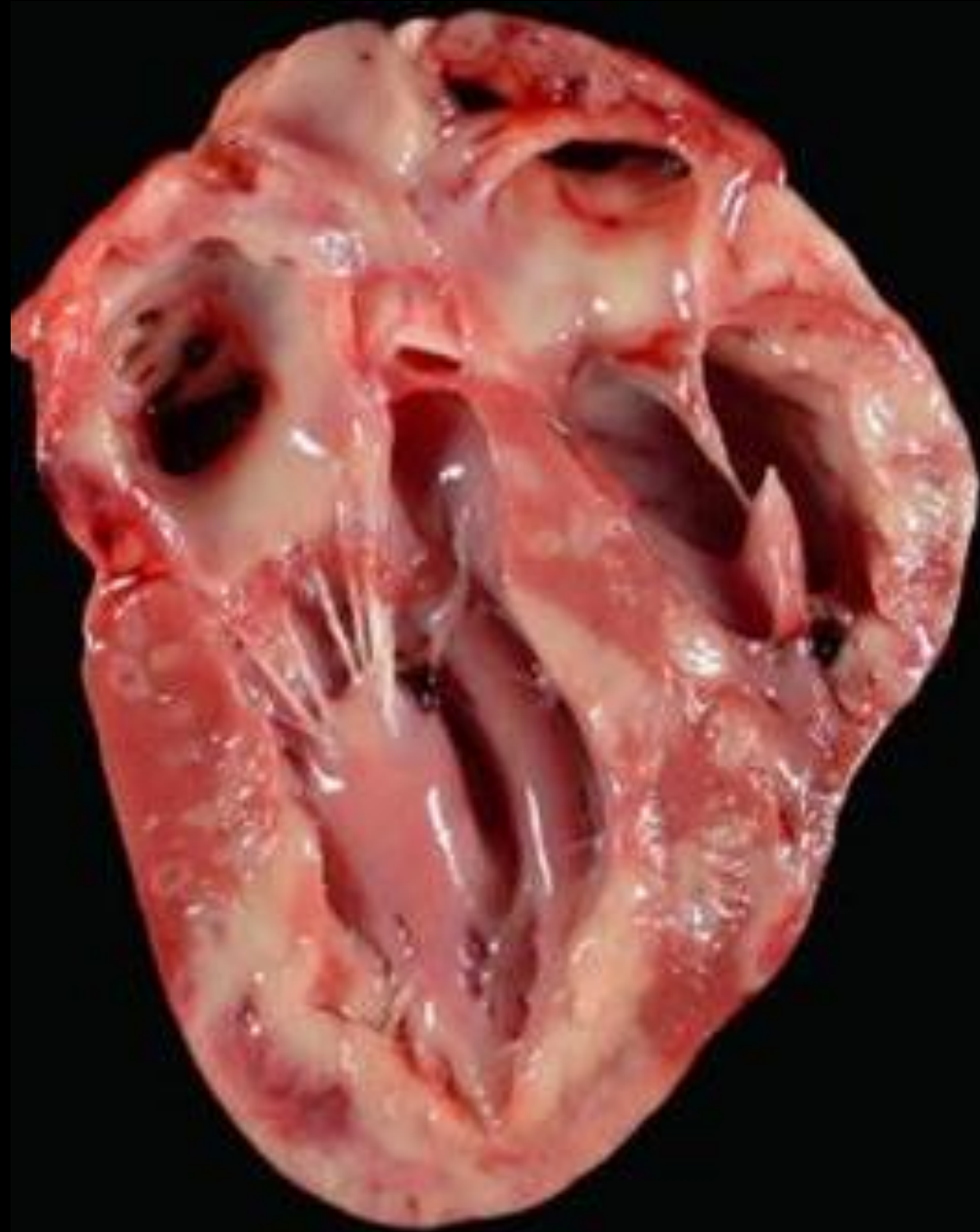
17

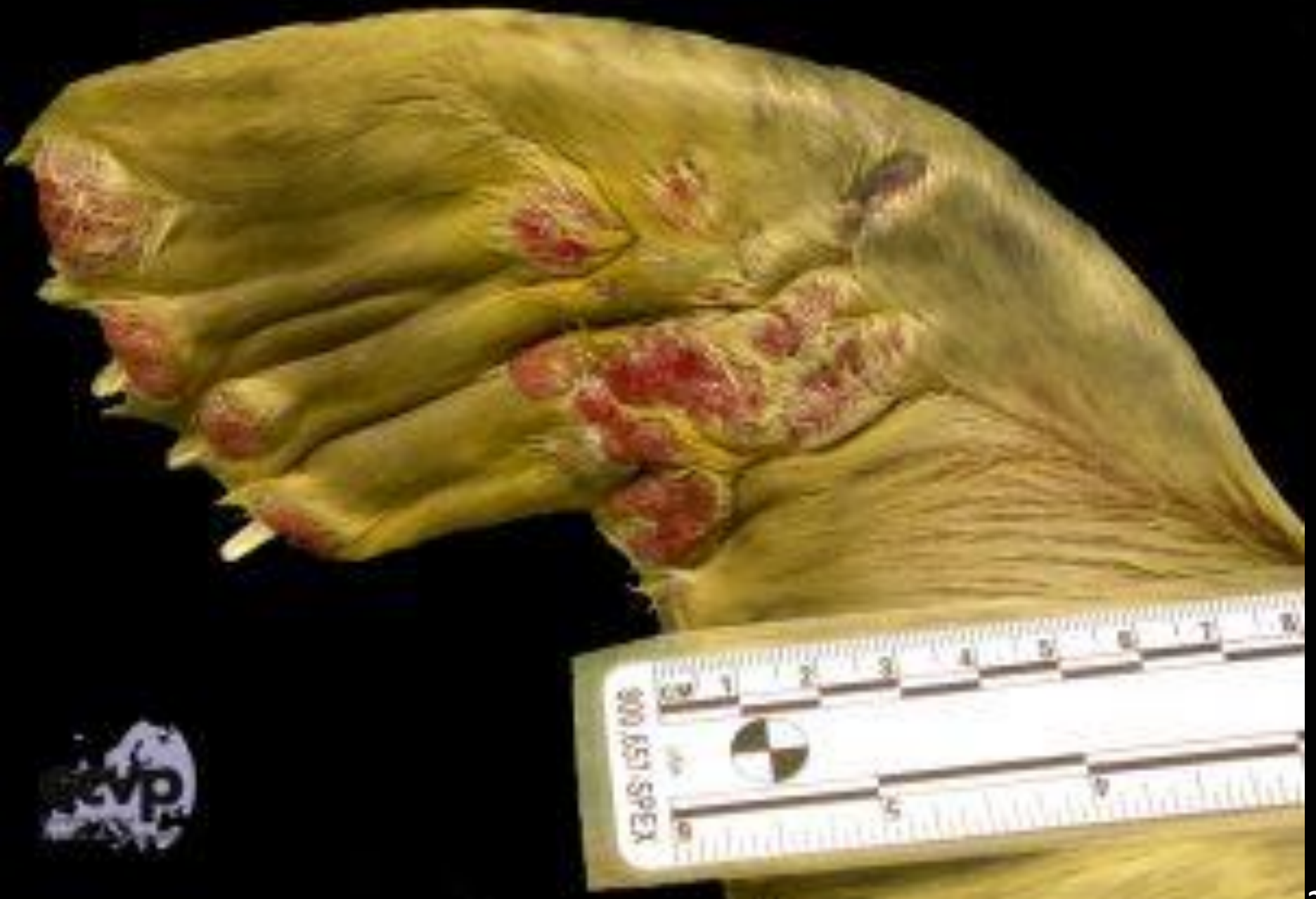

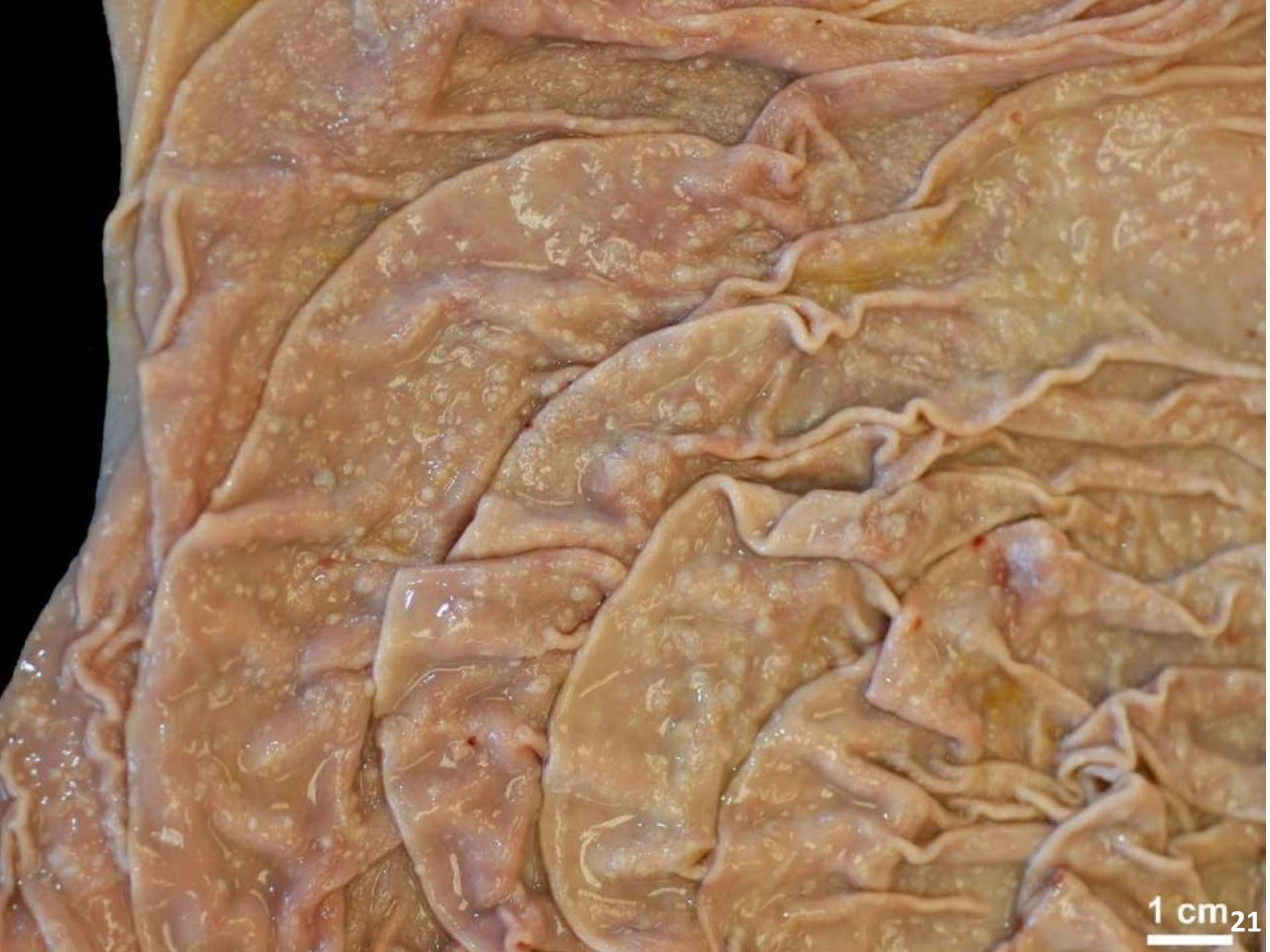The University of
Nottingham

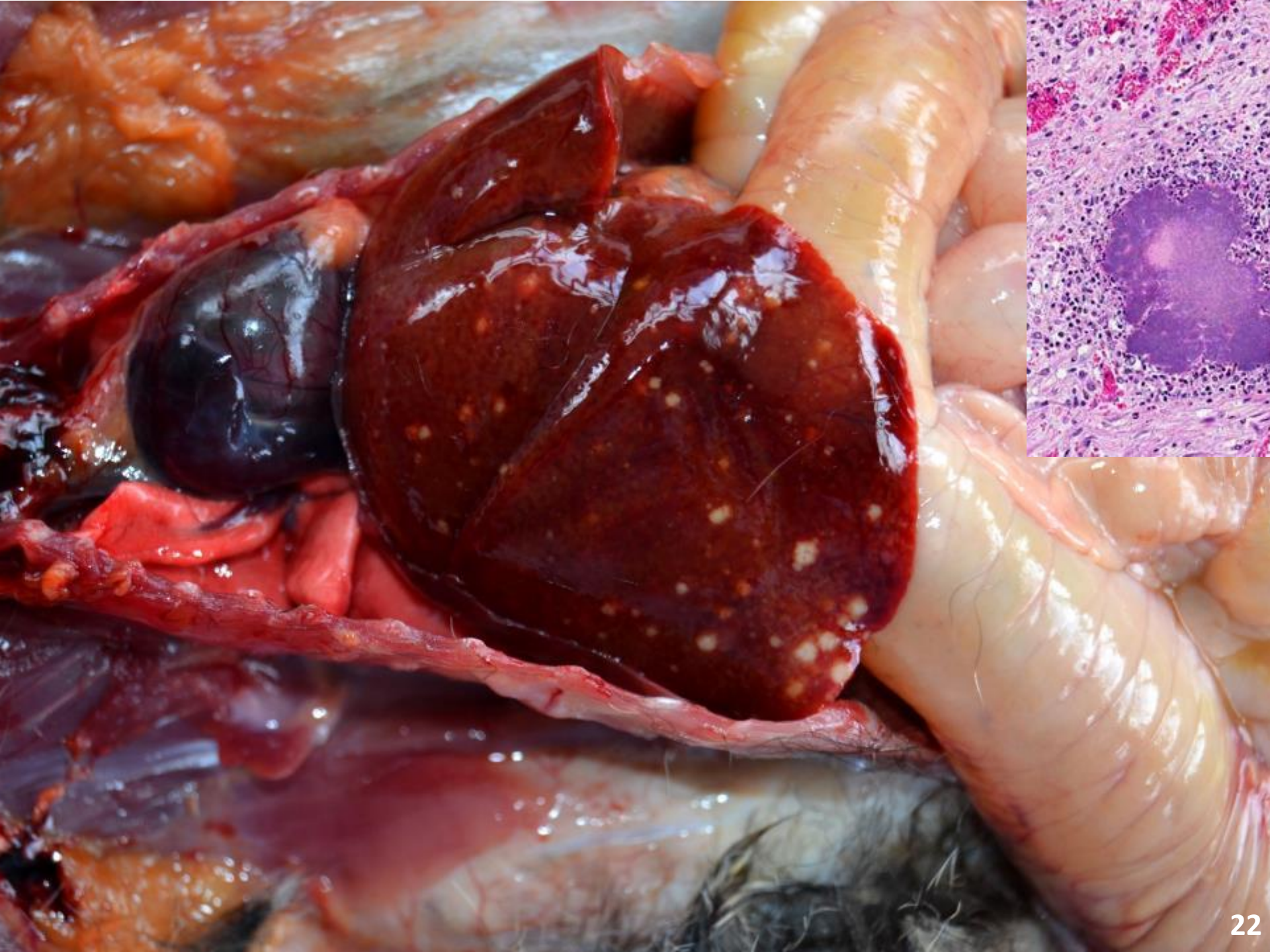


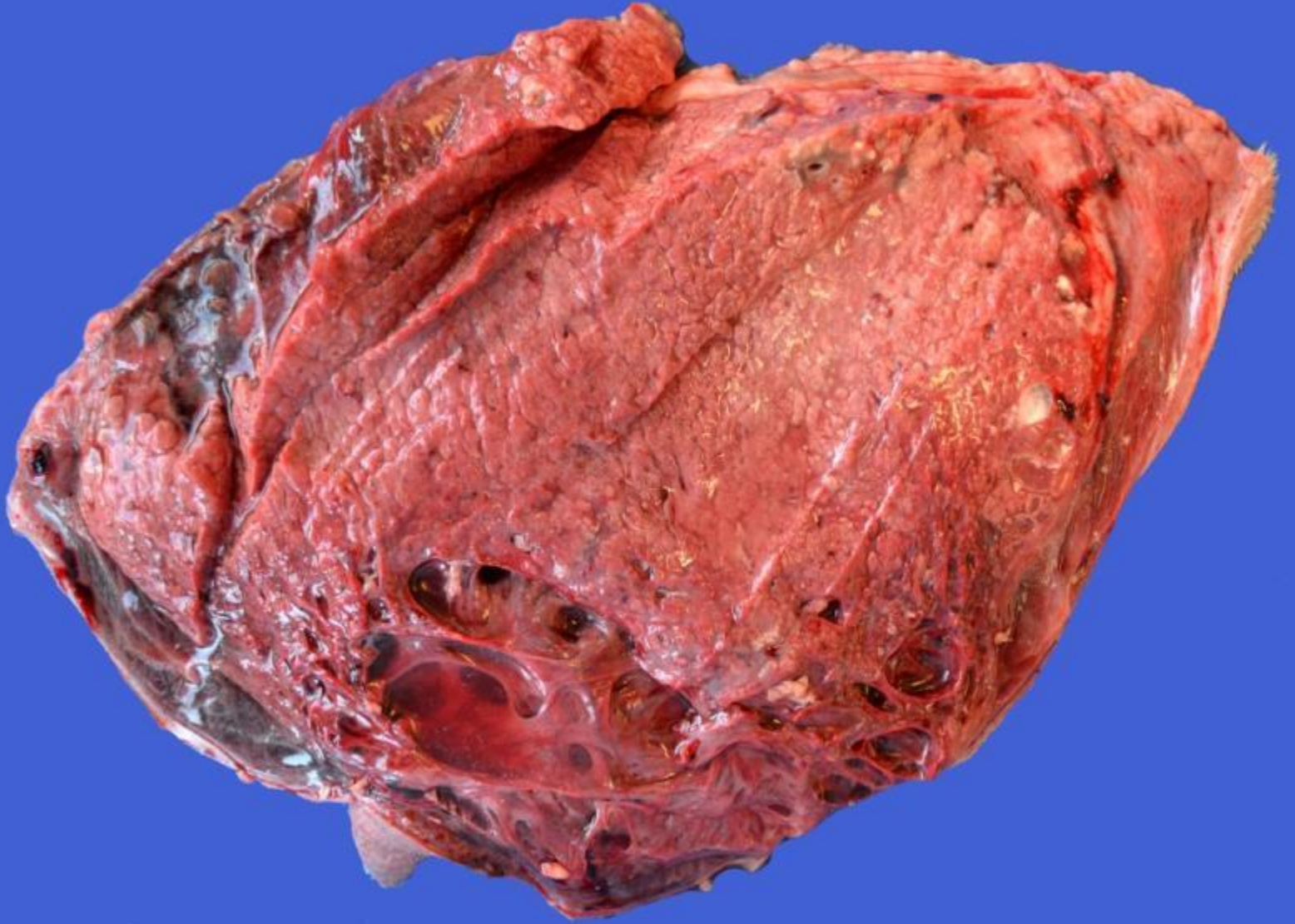


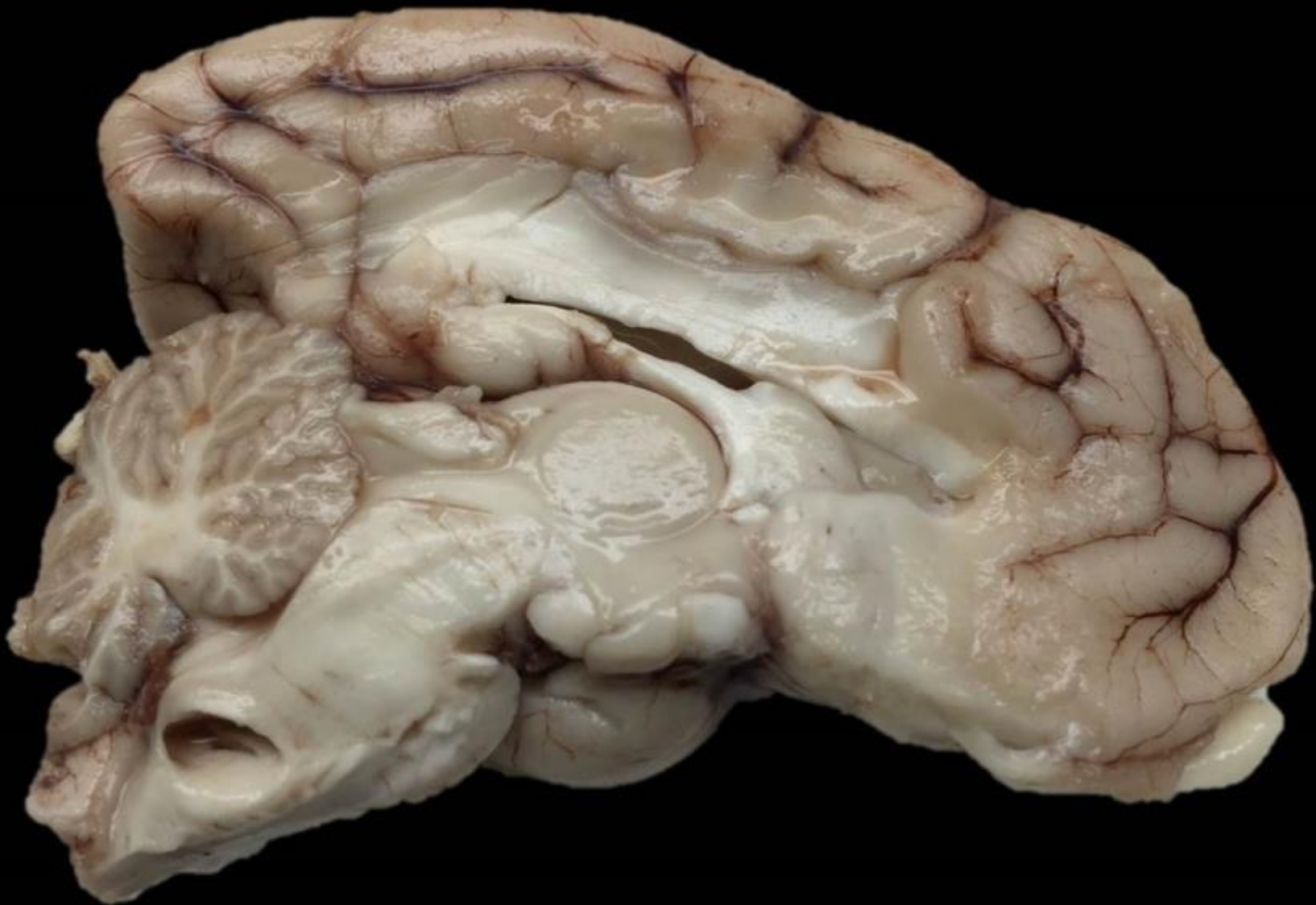
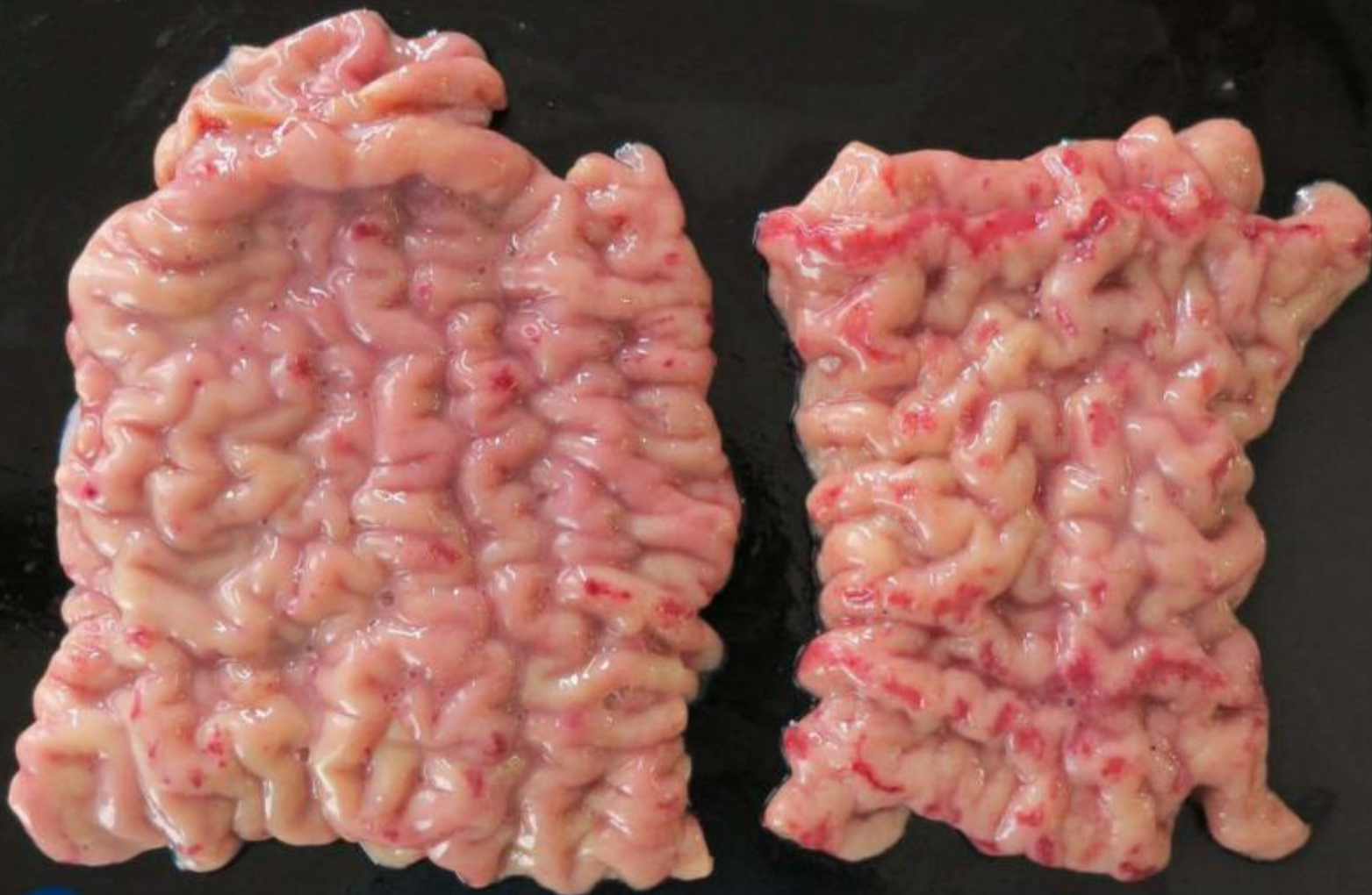










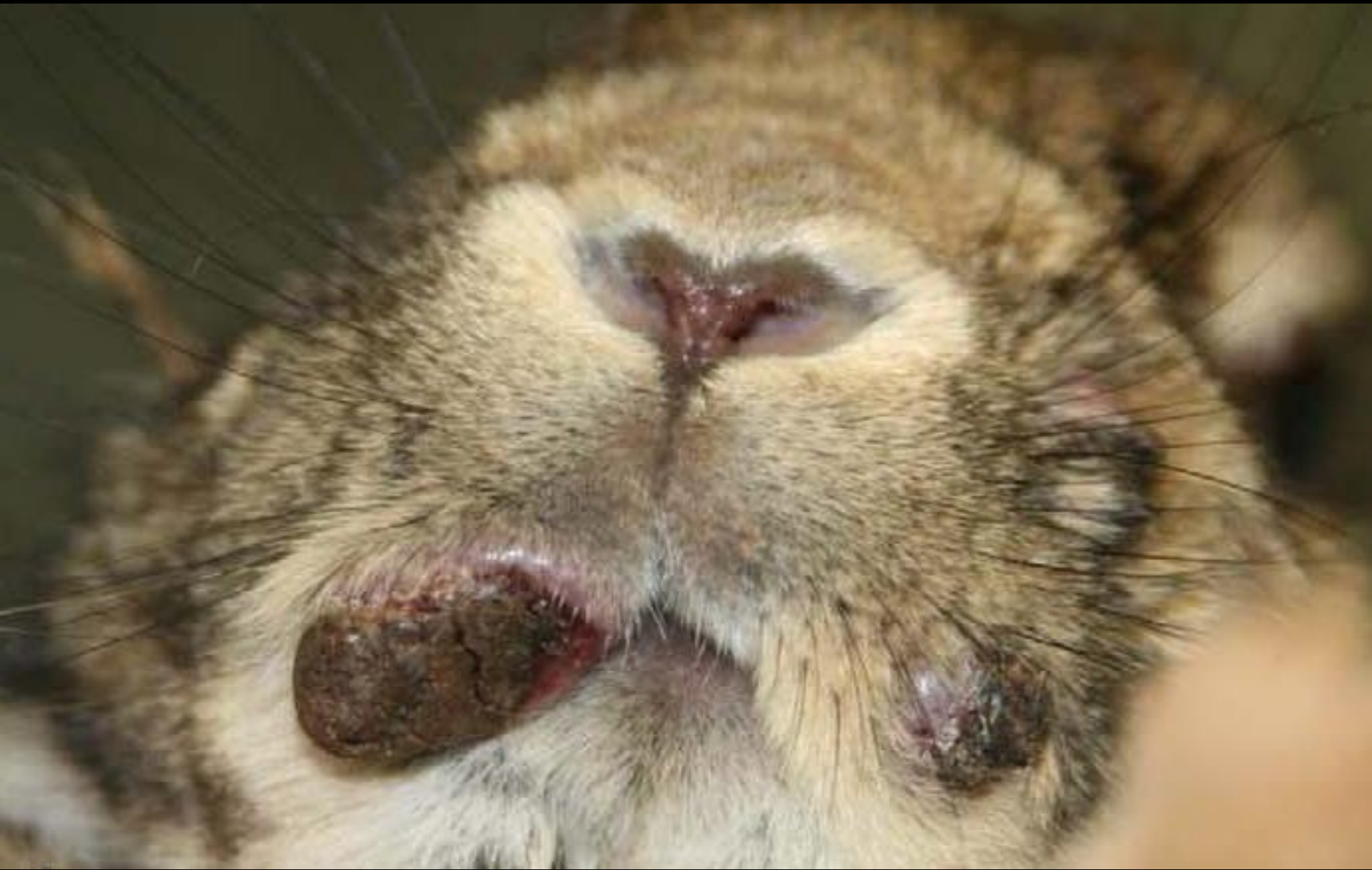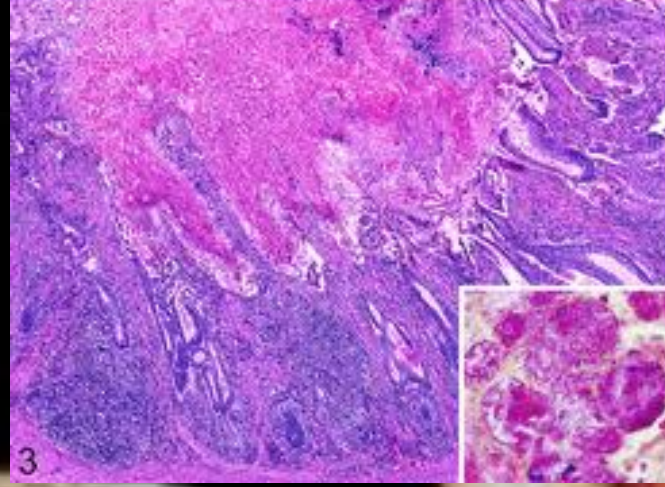


UNIVERSIDAD DE LAS PALMAS DE GRAN CANARIA

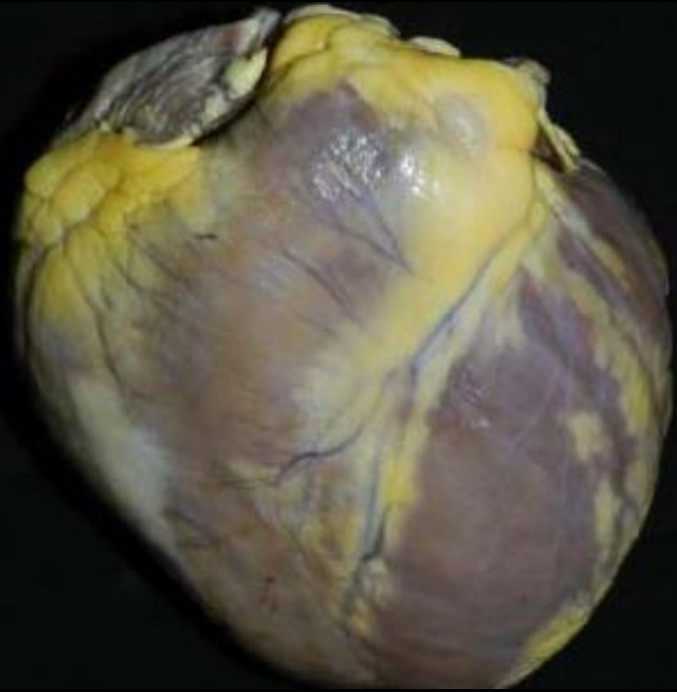Departamento de Morfología



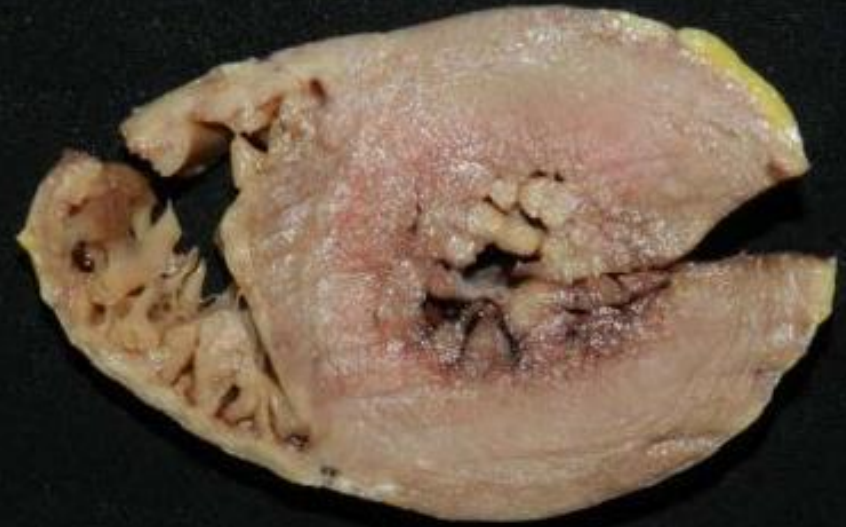







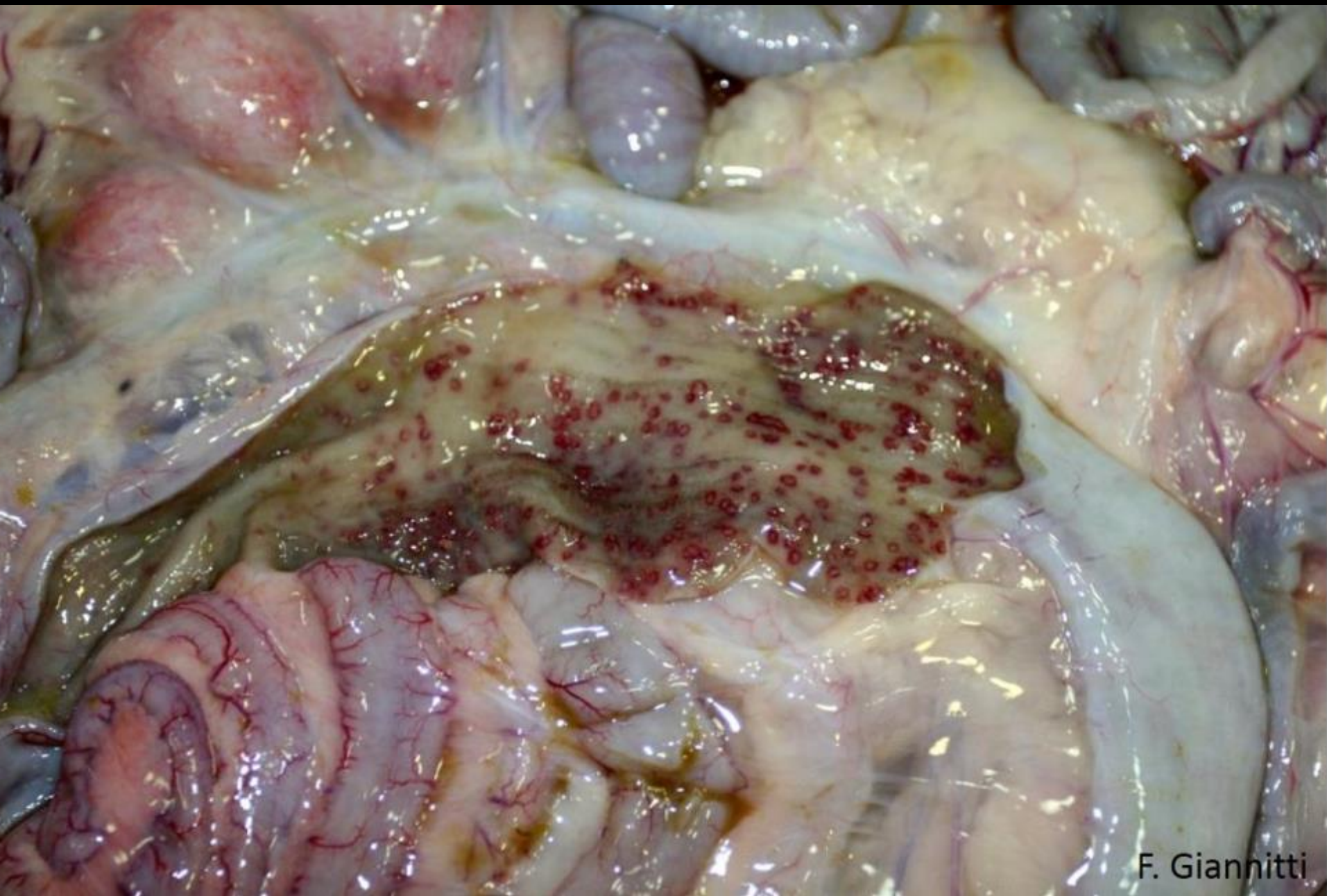13



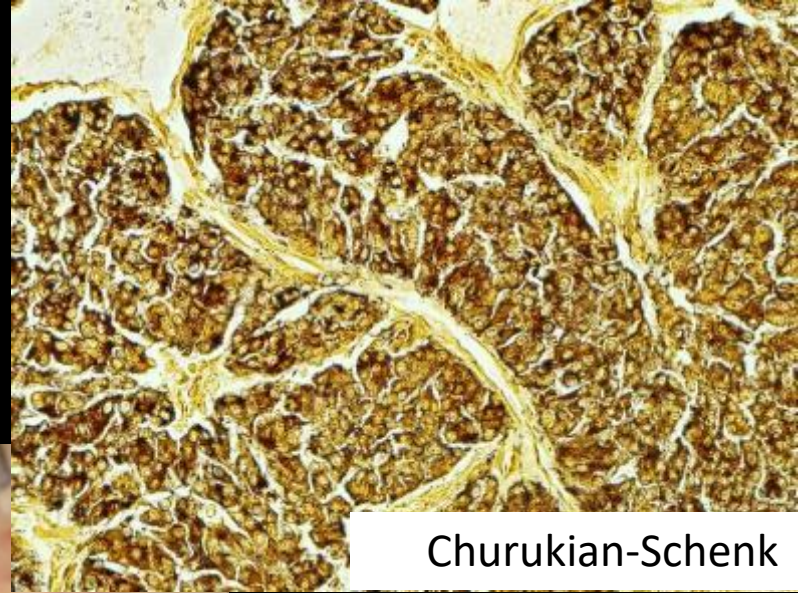
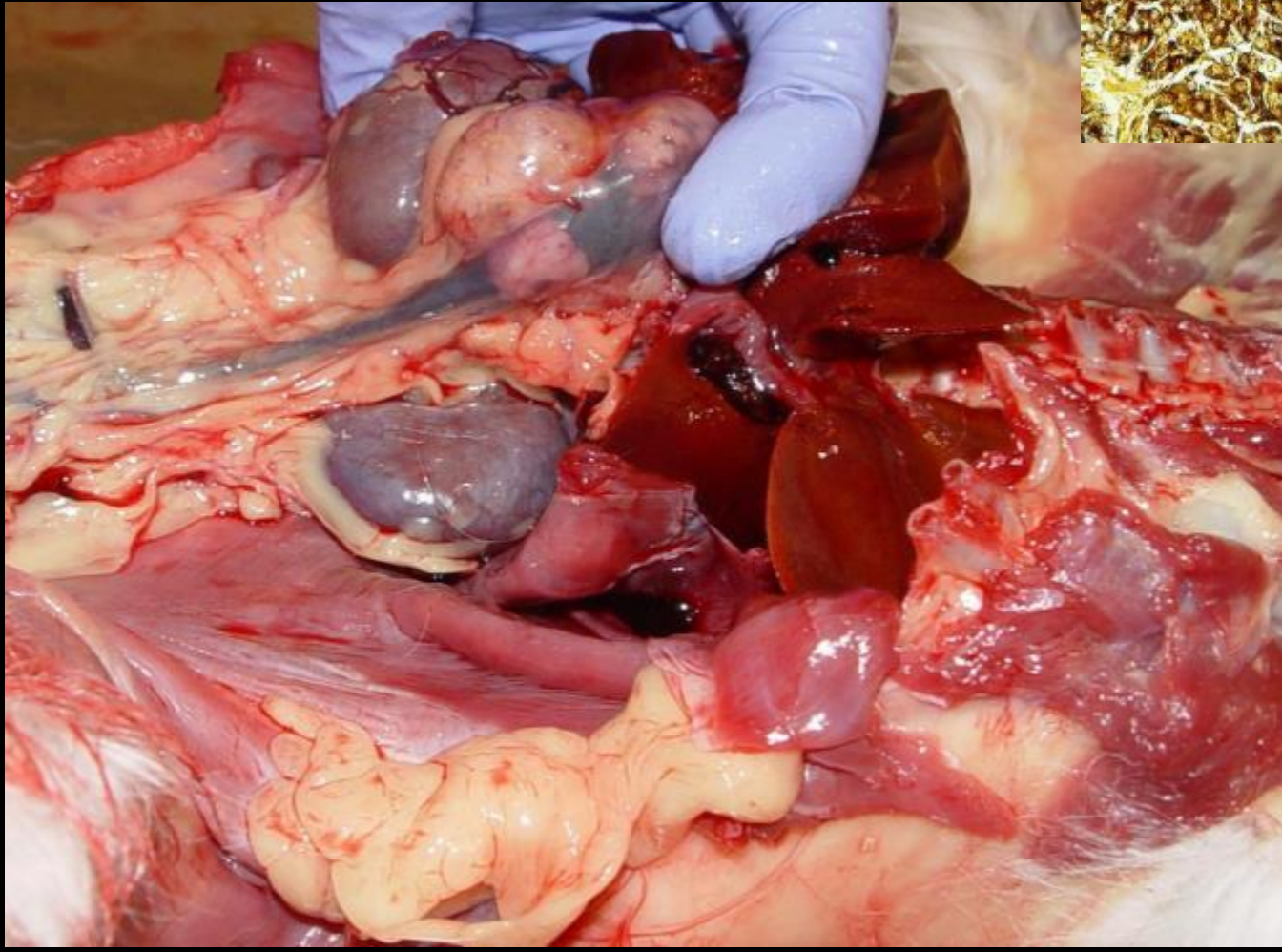
14



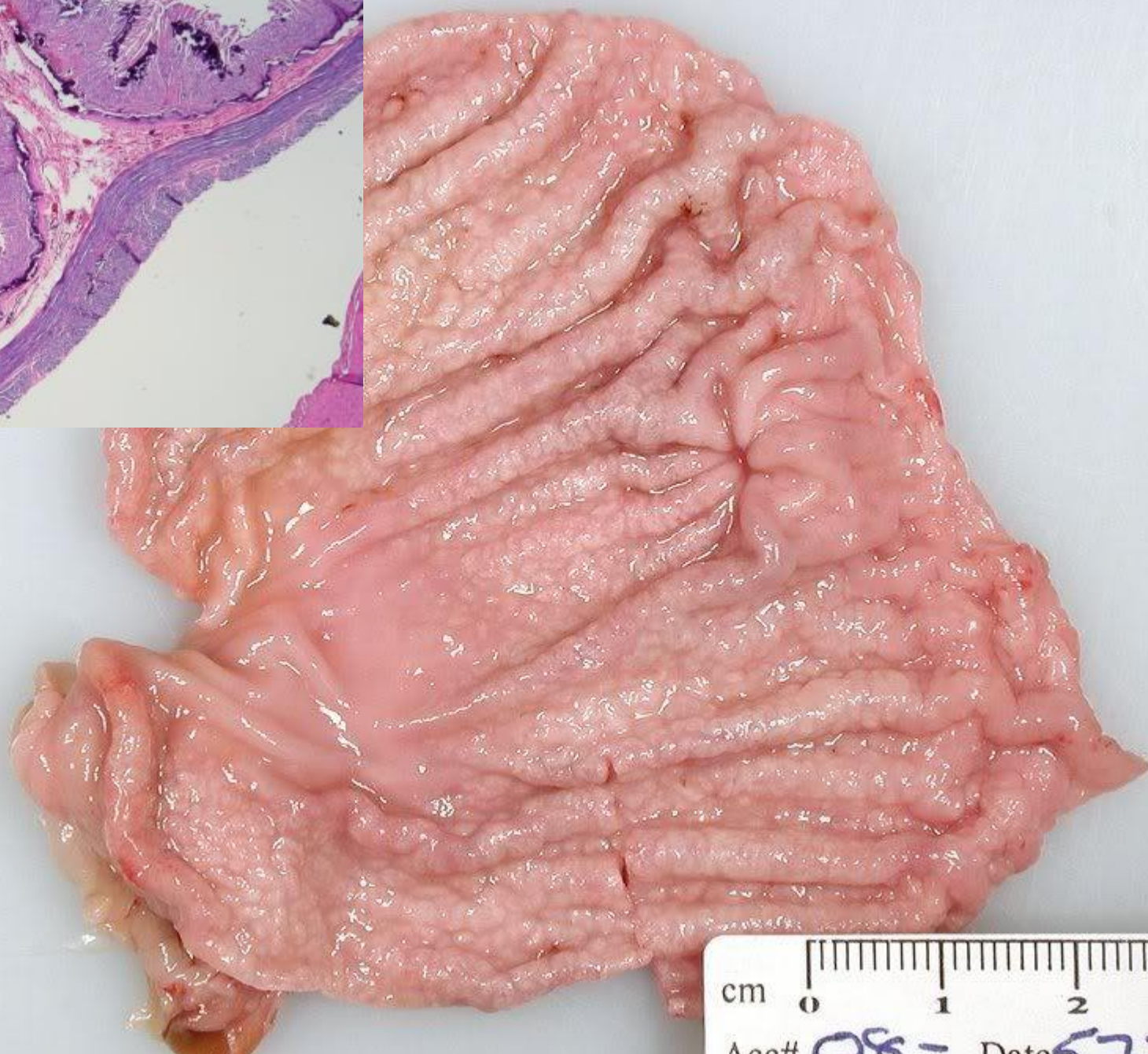
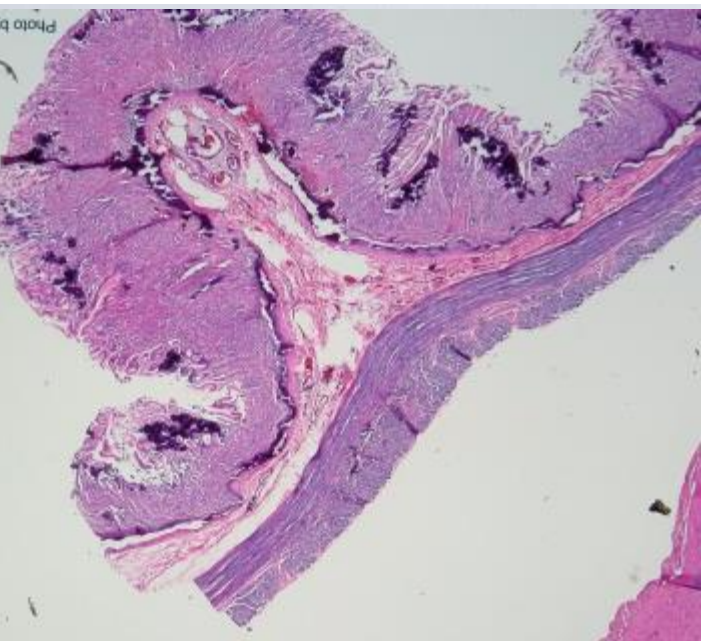
4



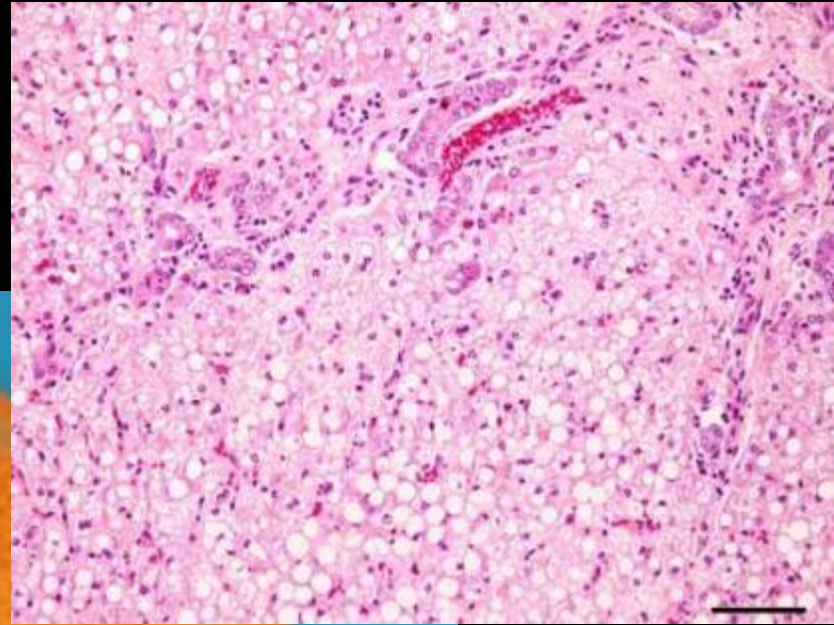
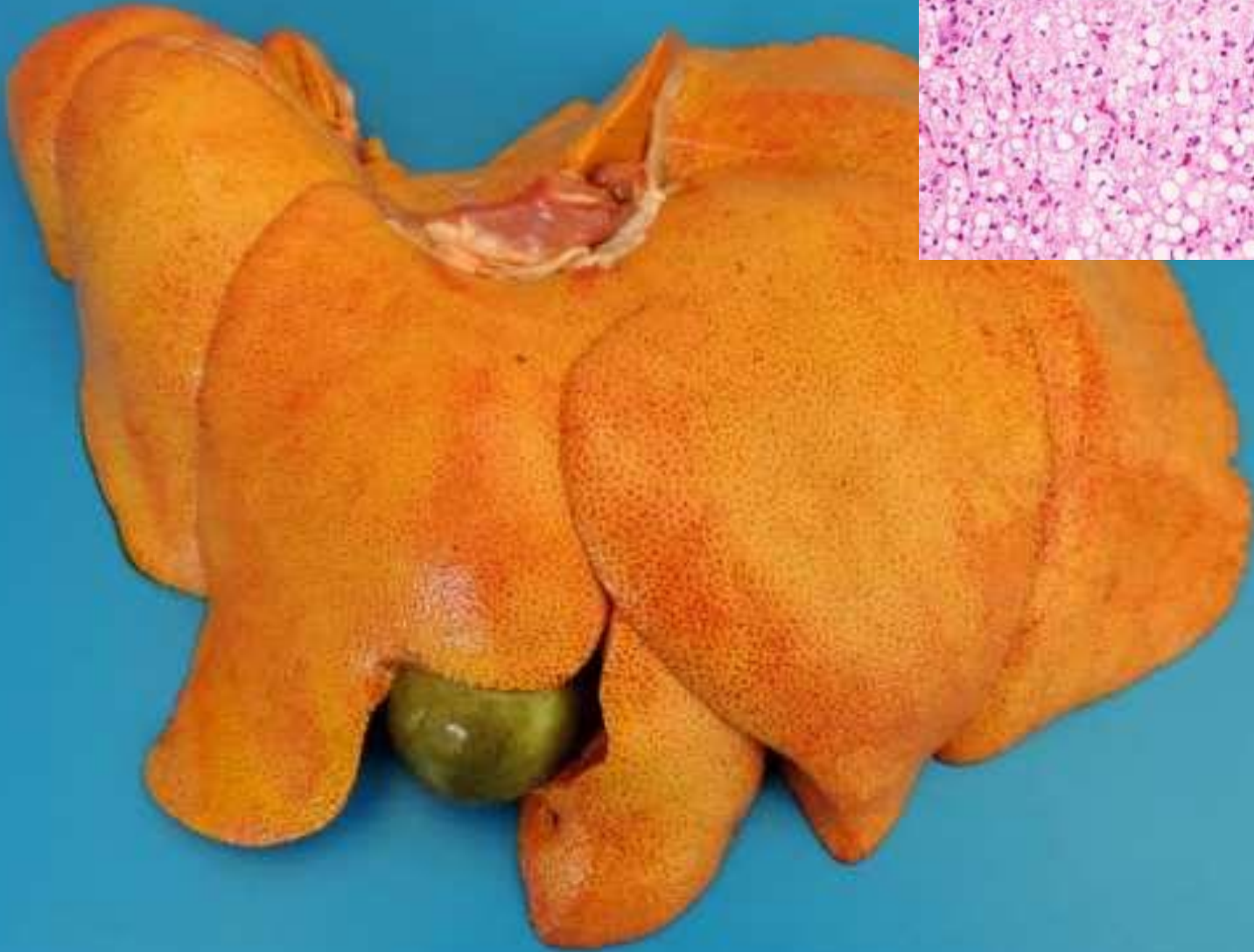
F. Giannitti

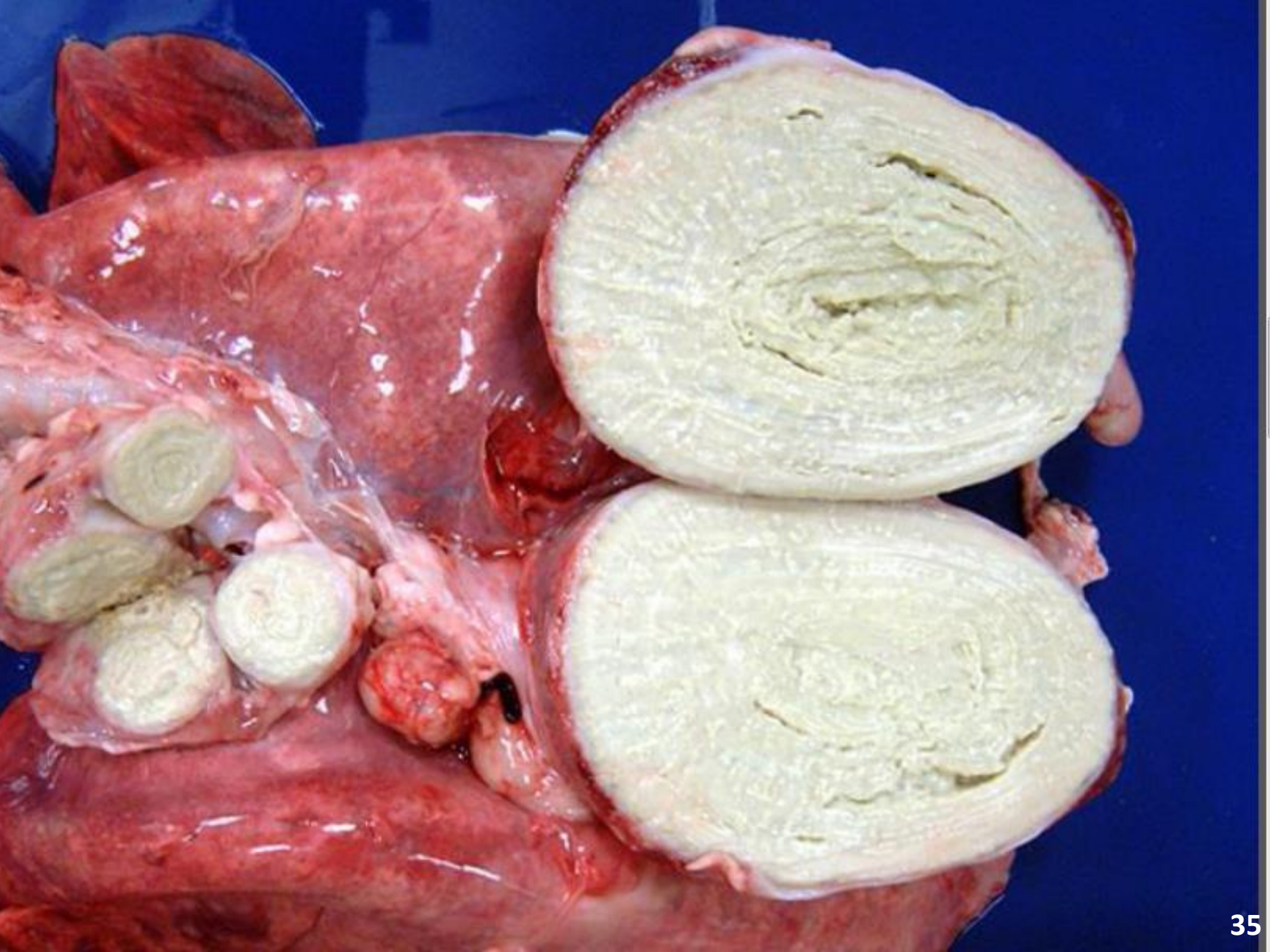


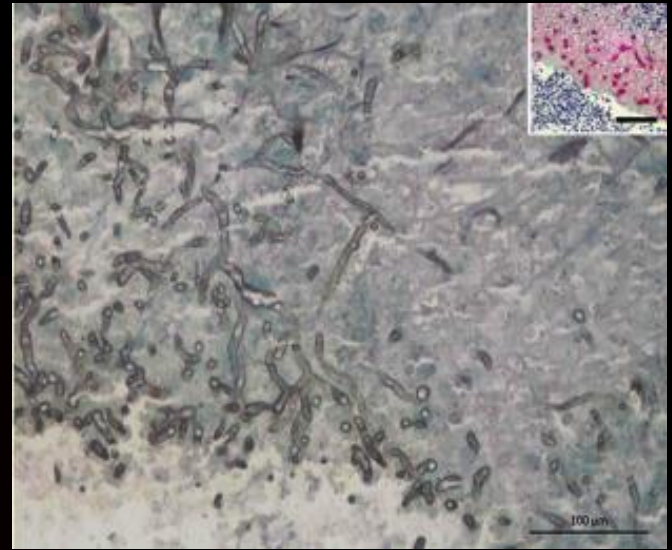
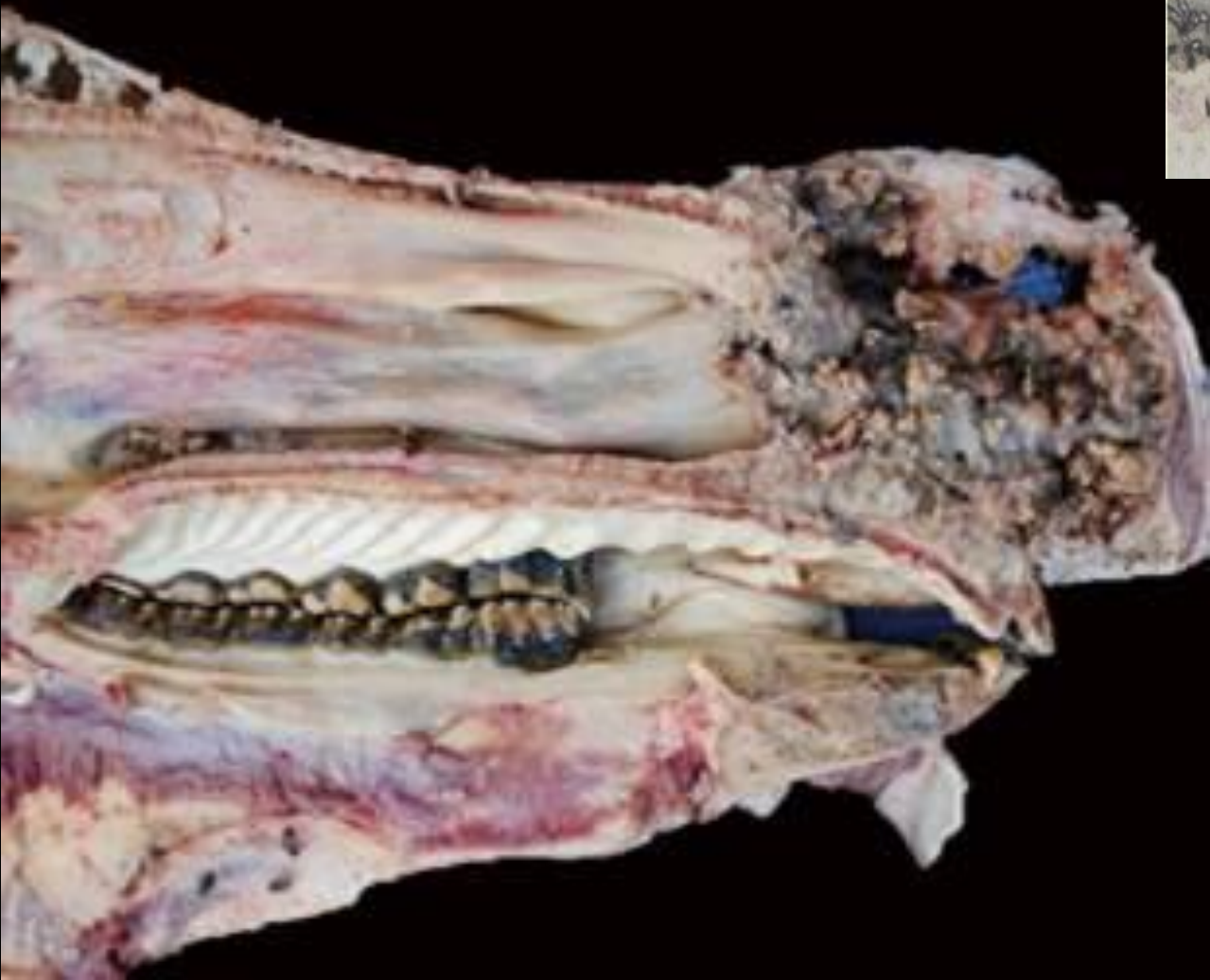Churukian-Schenk

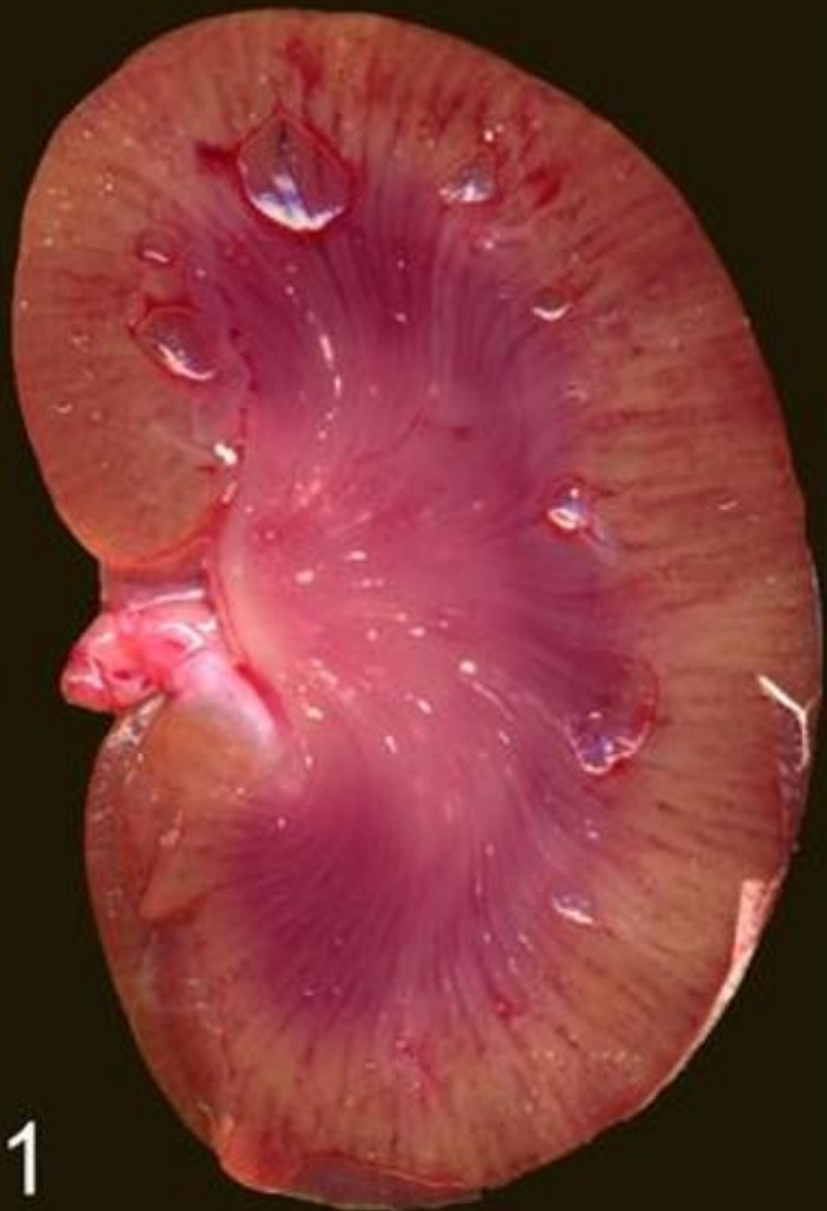

cm 0 1 2 3 33
Acct# 08 = Date 57324

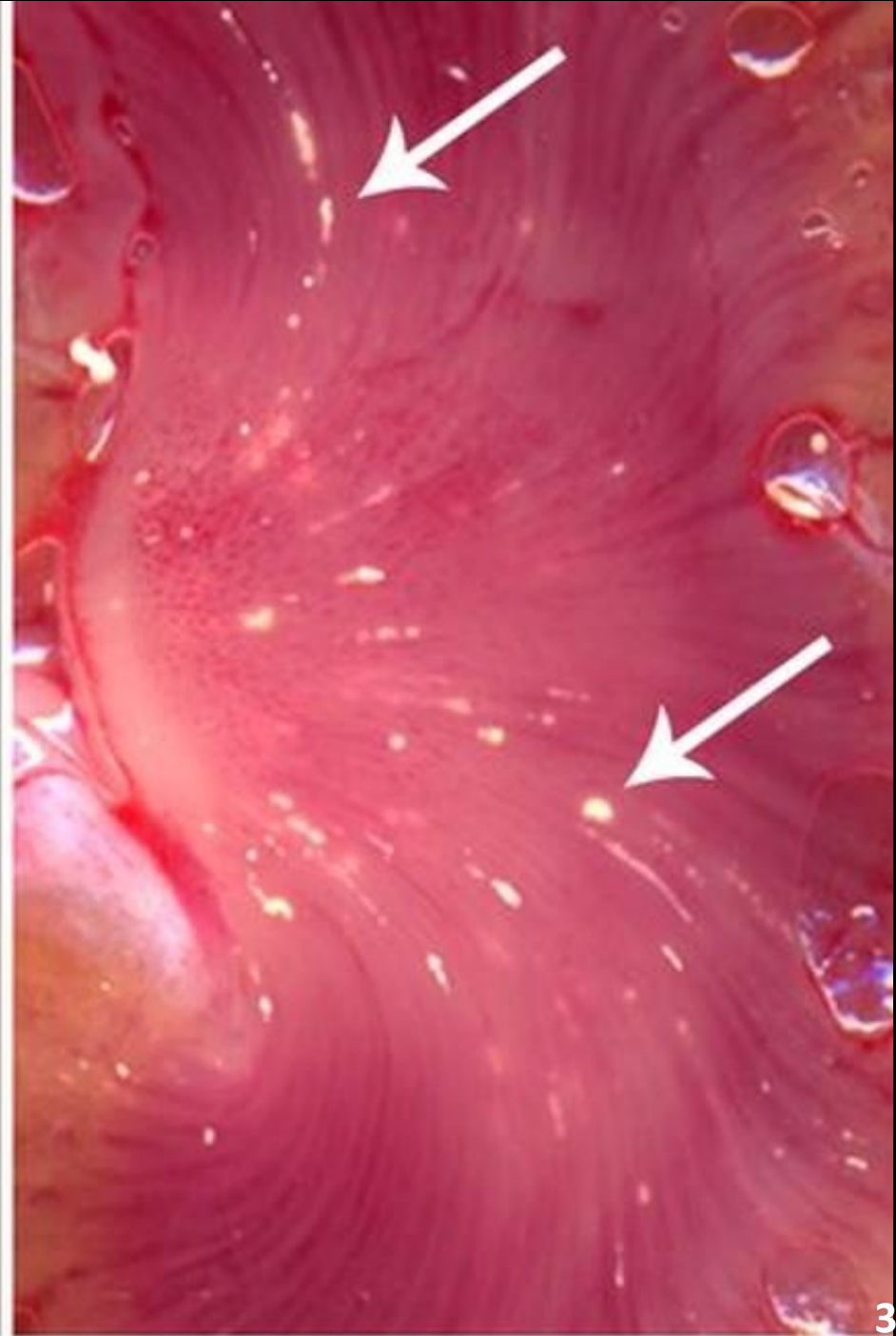




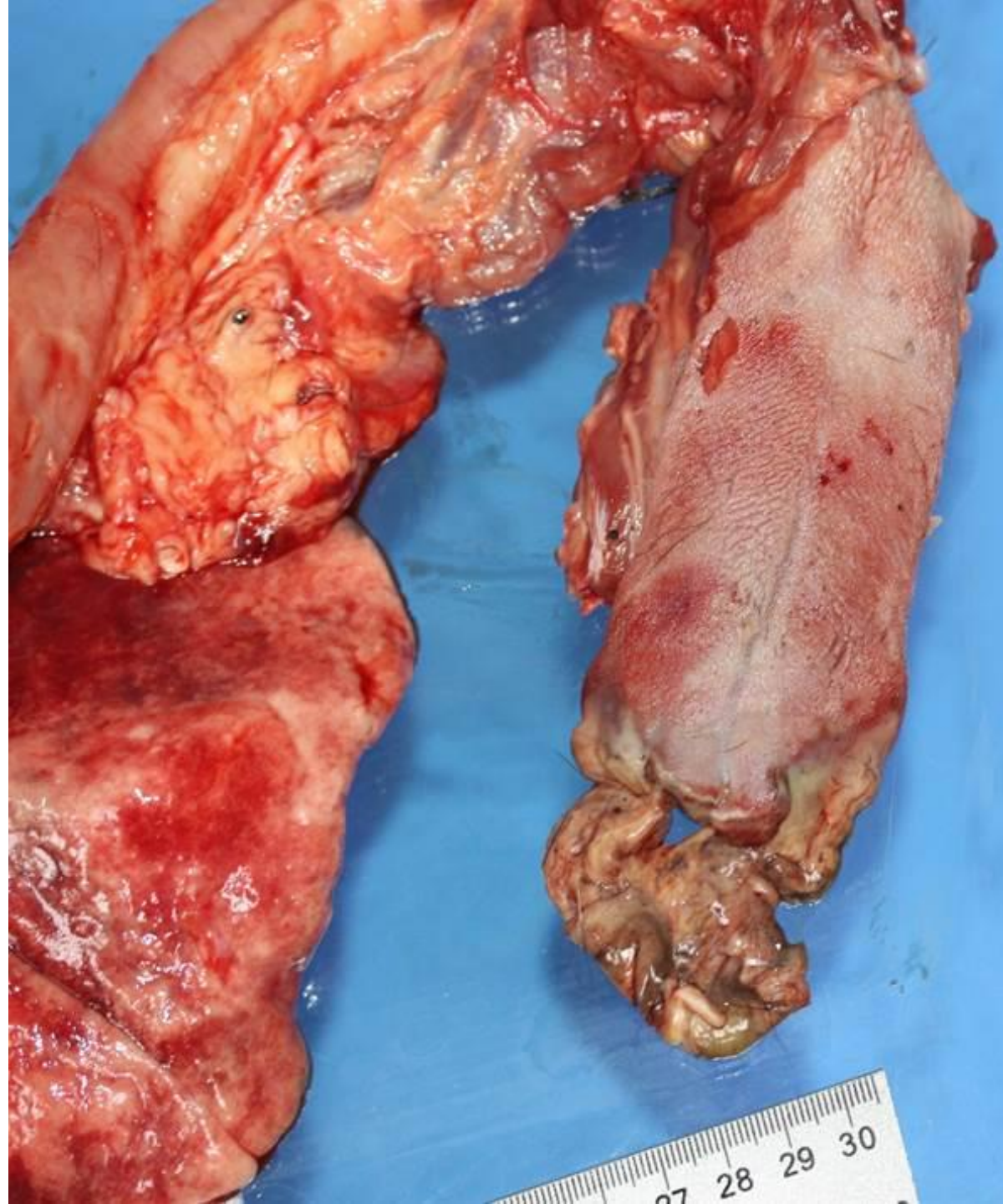


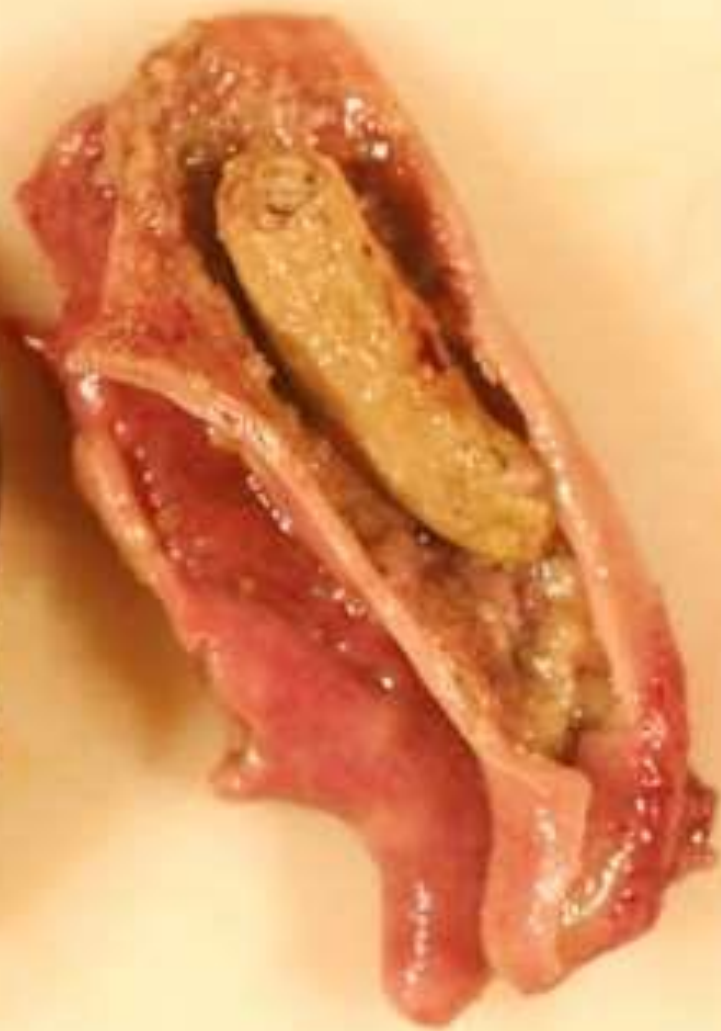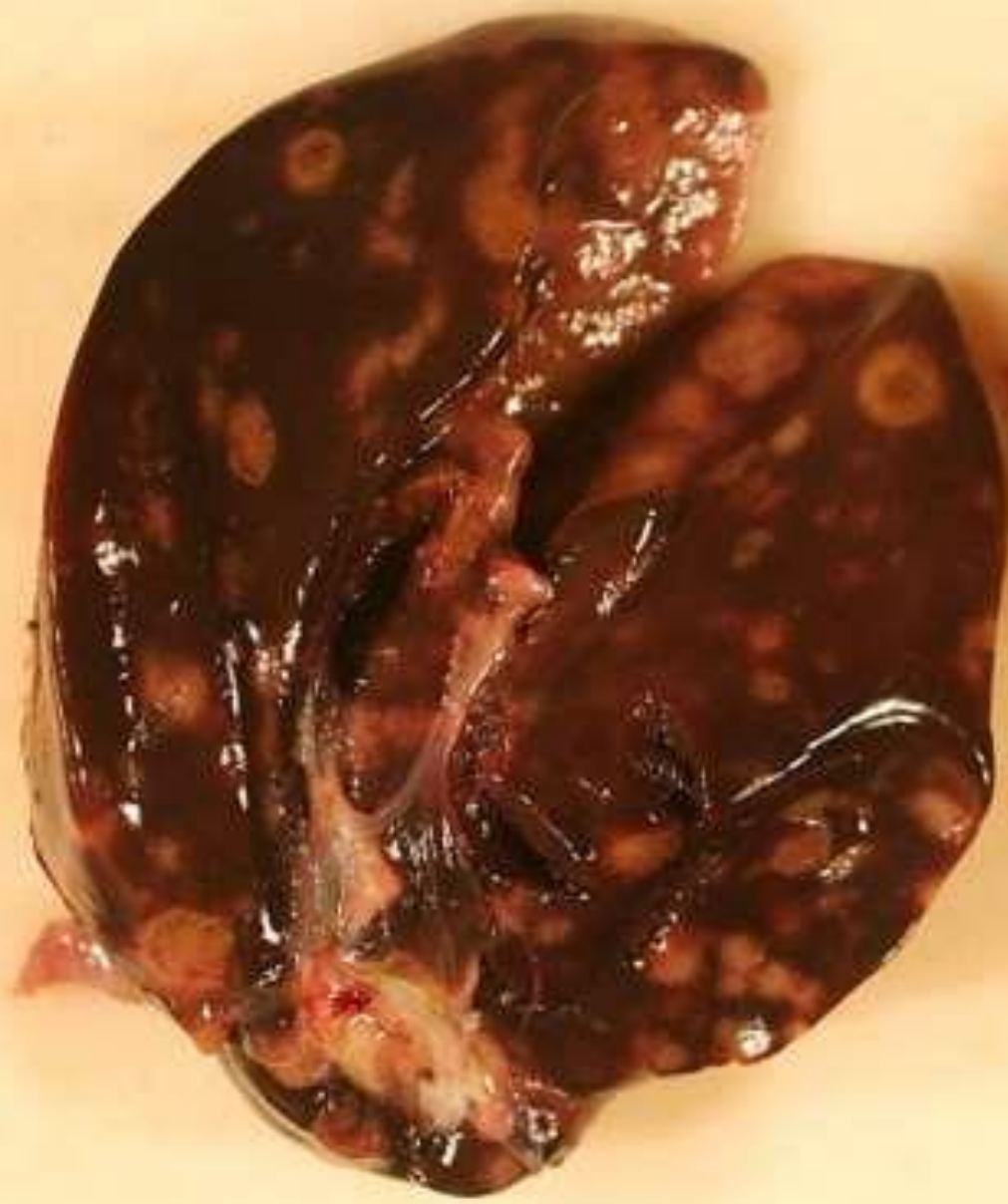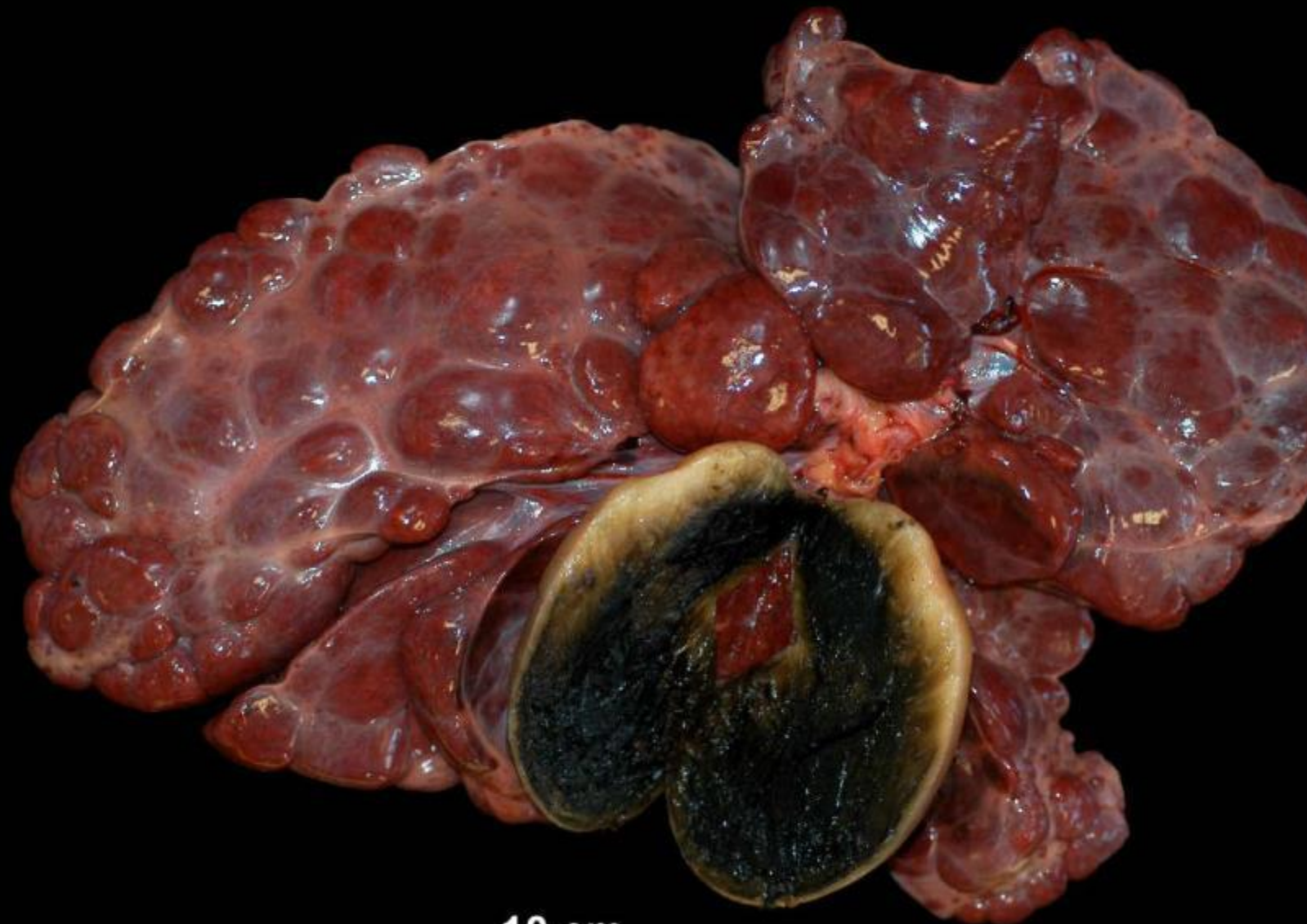1



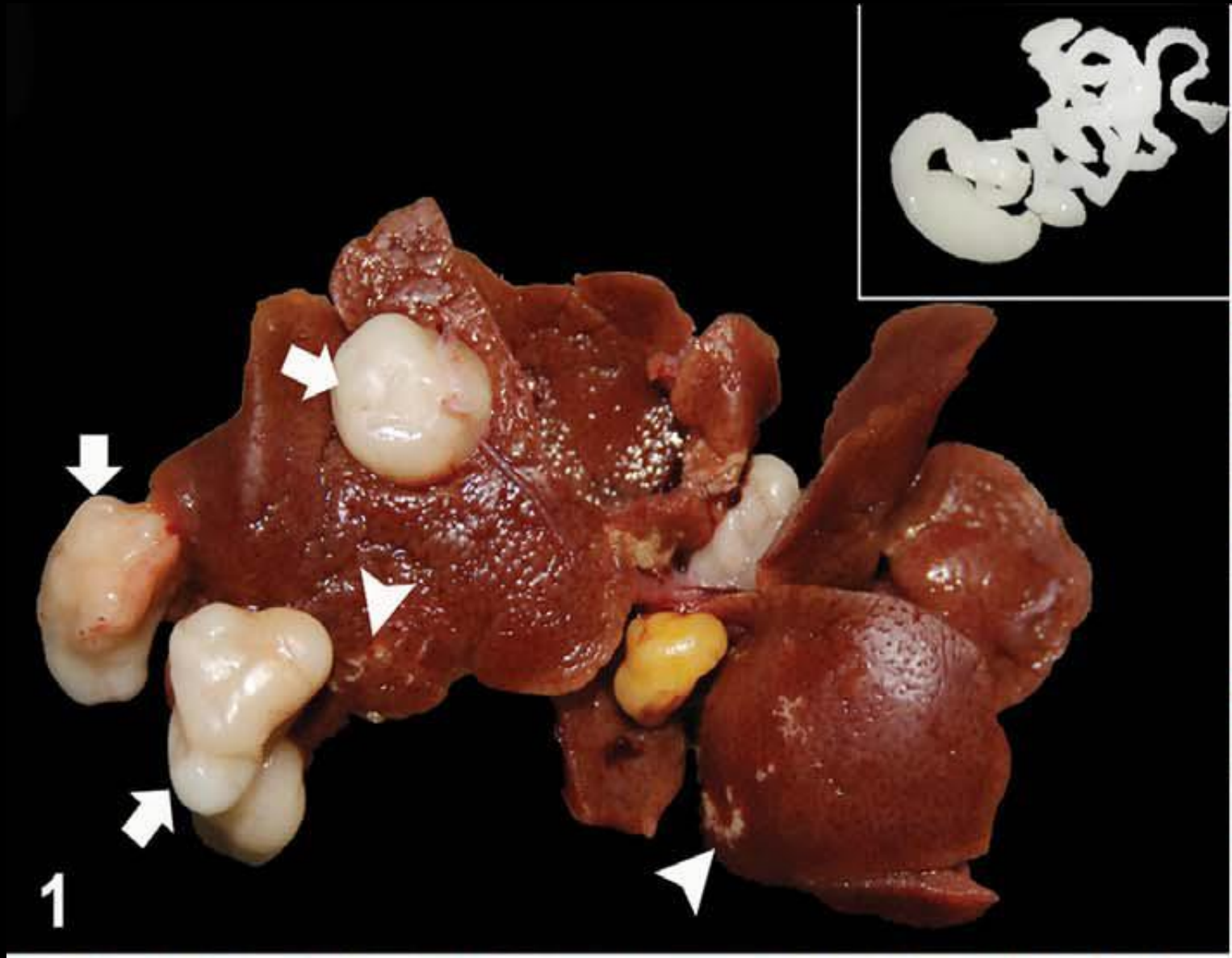37

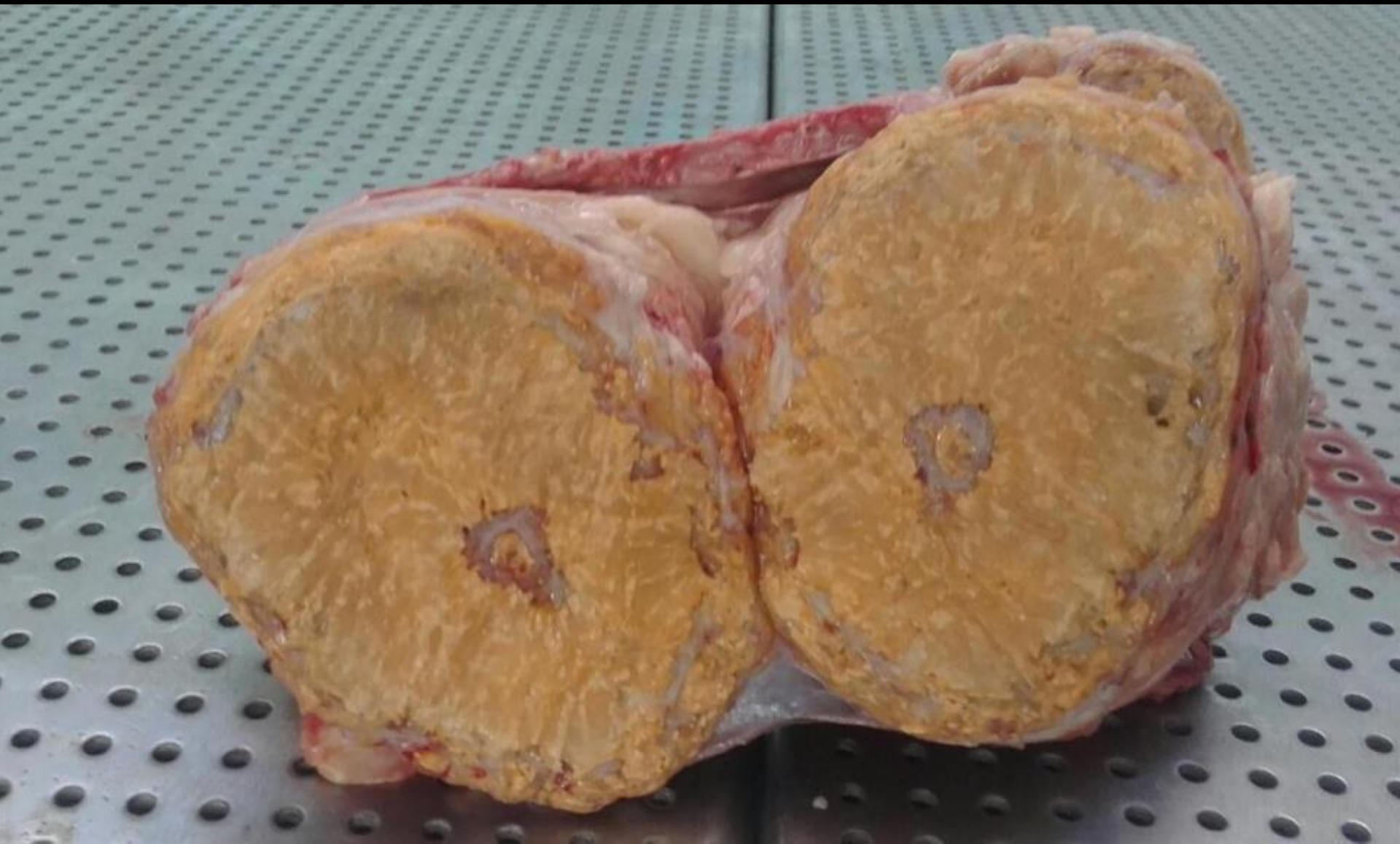


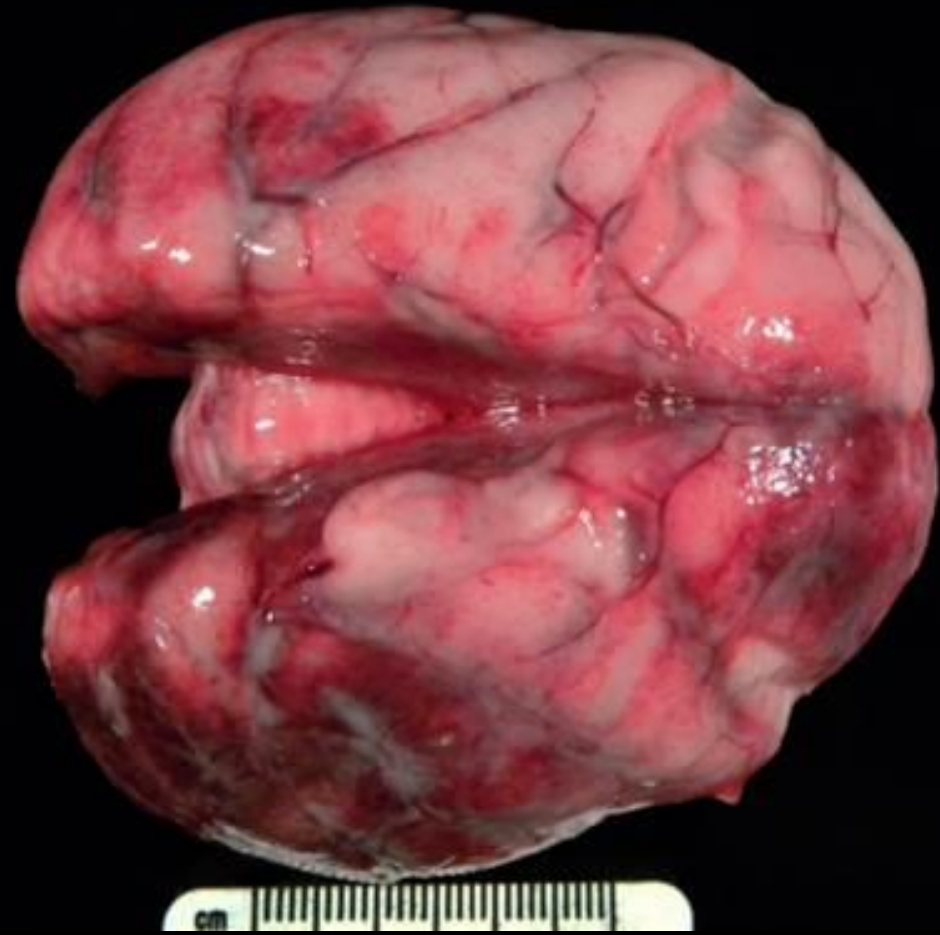
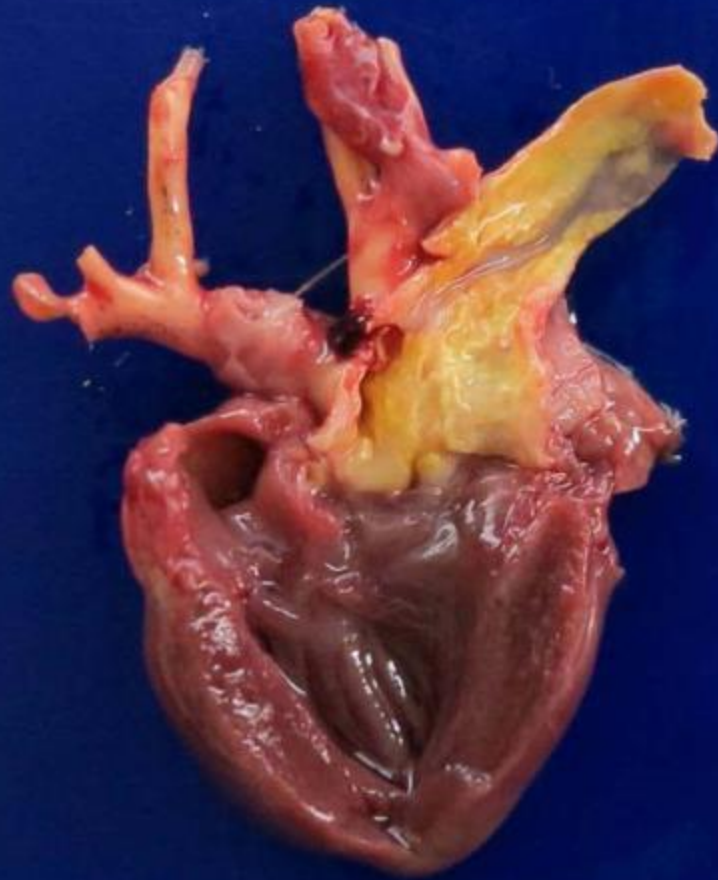


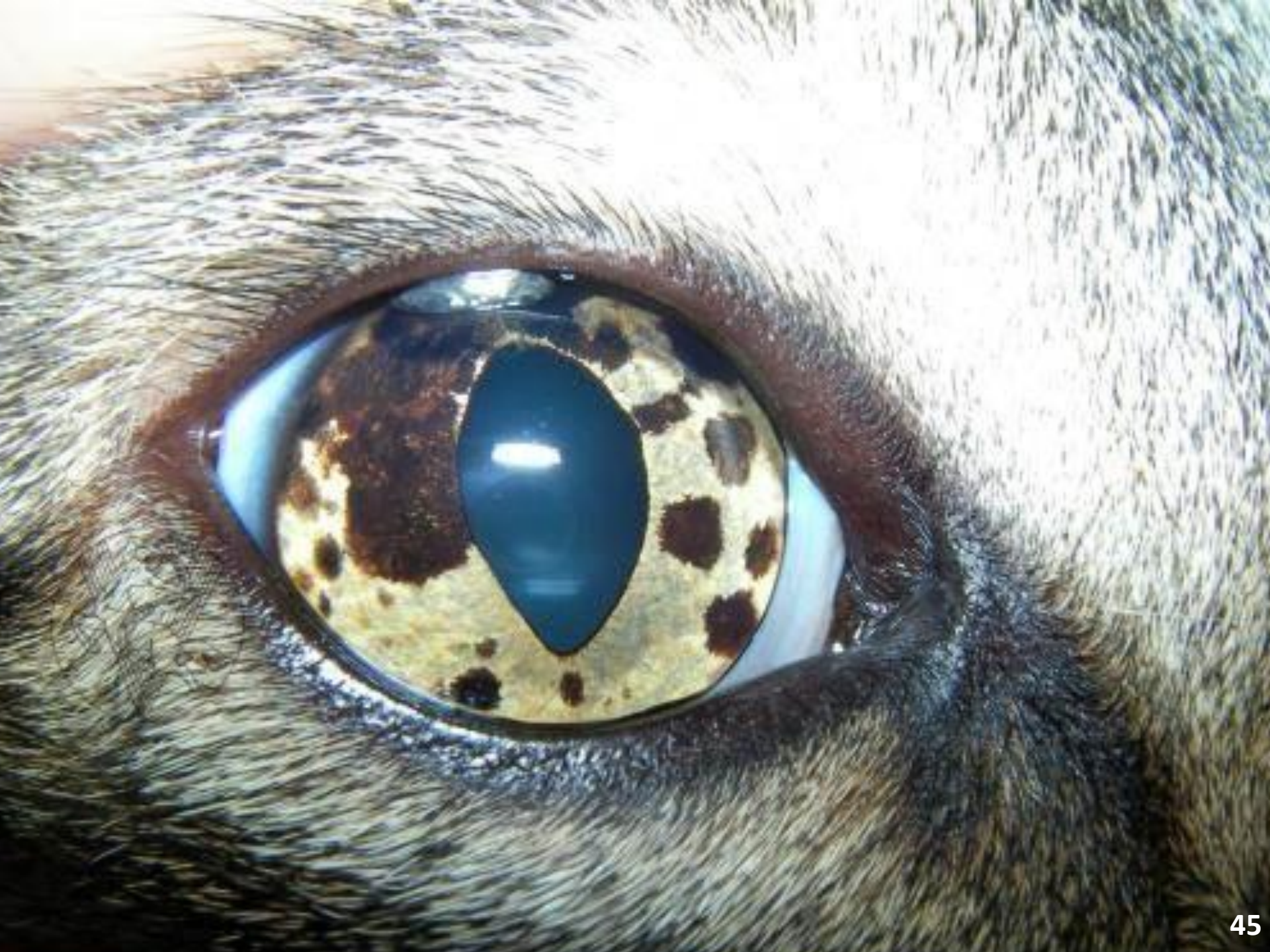10 cm

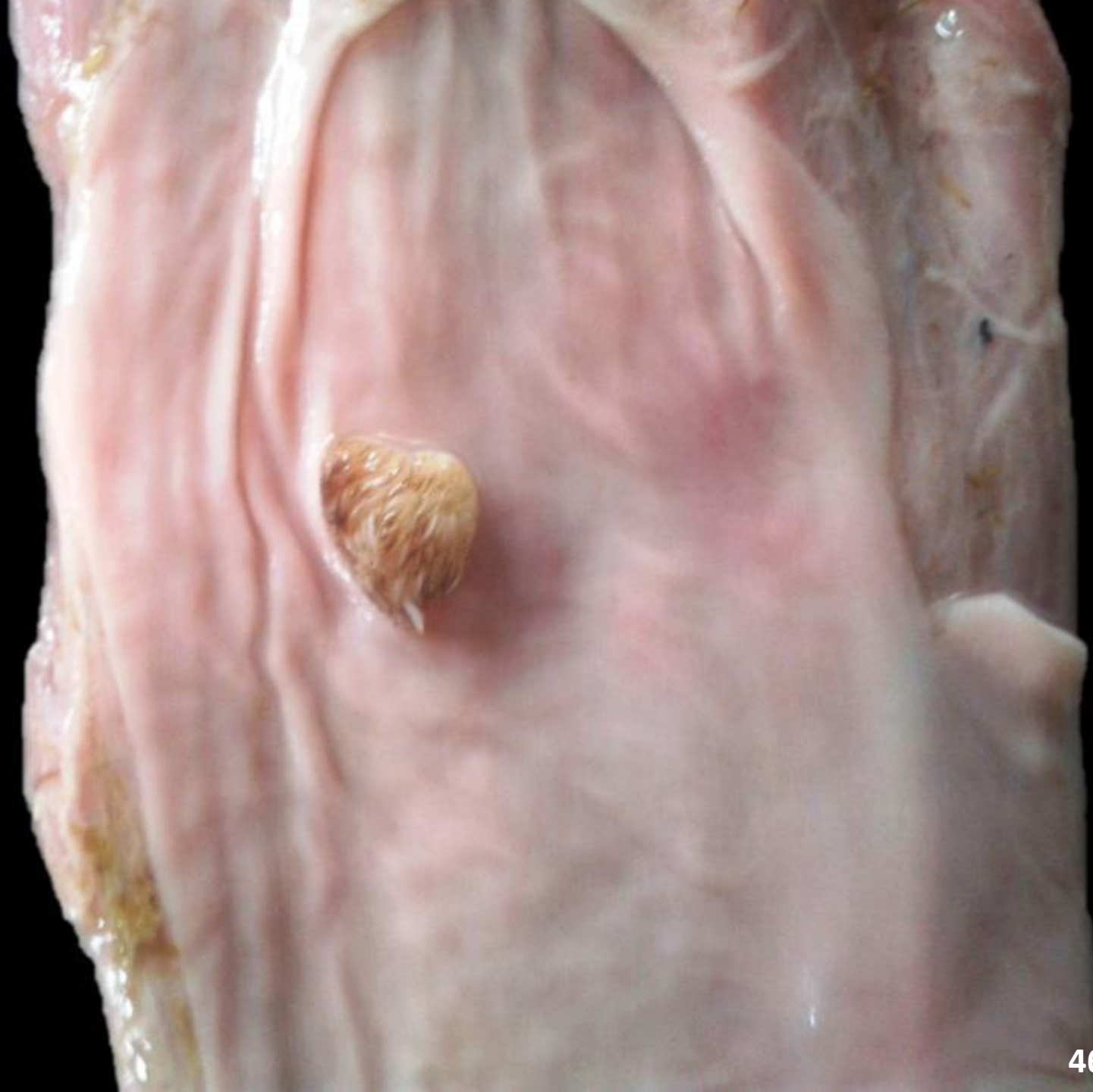

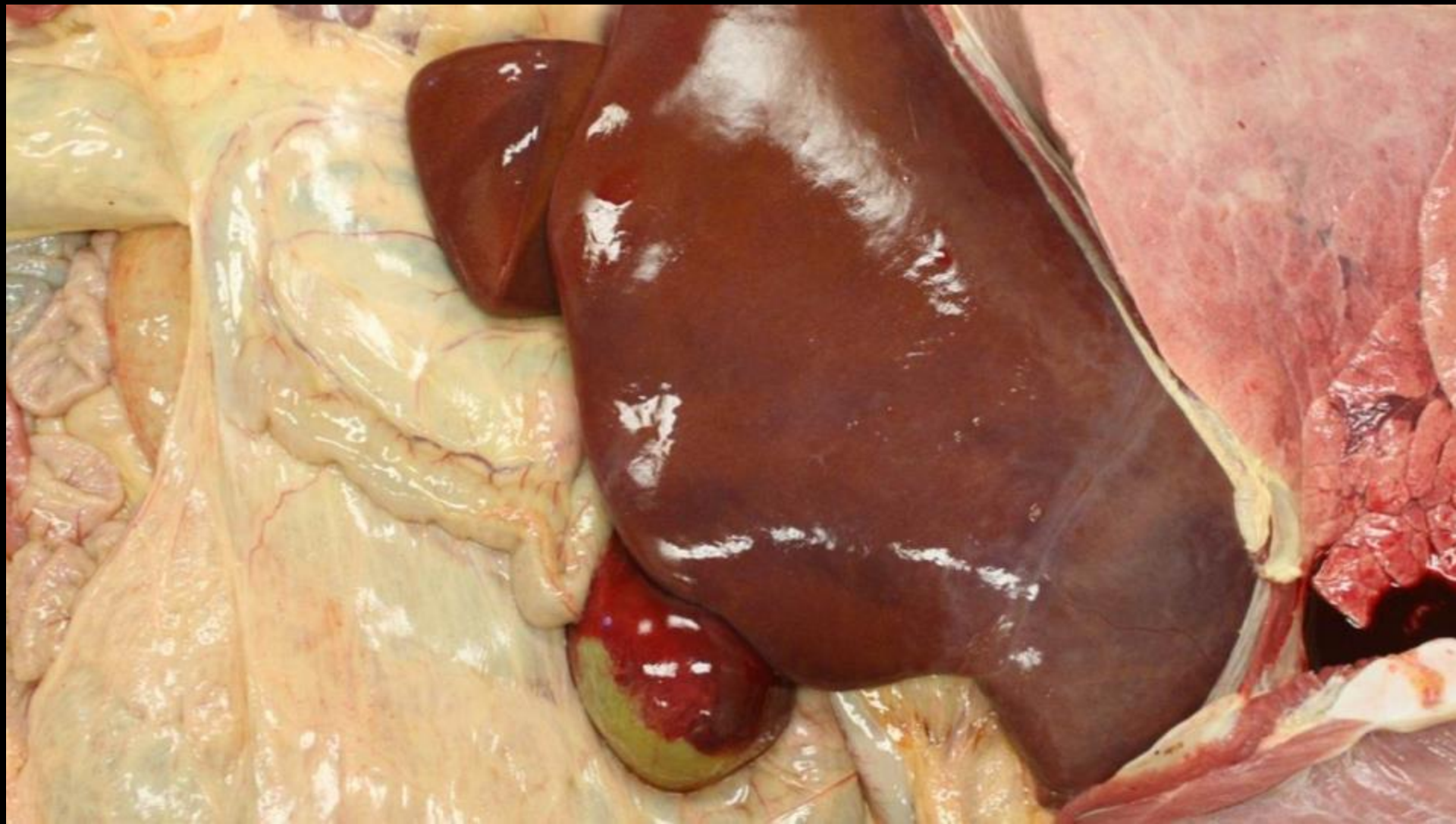



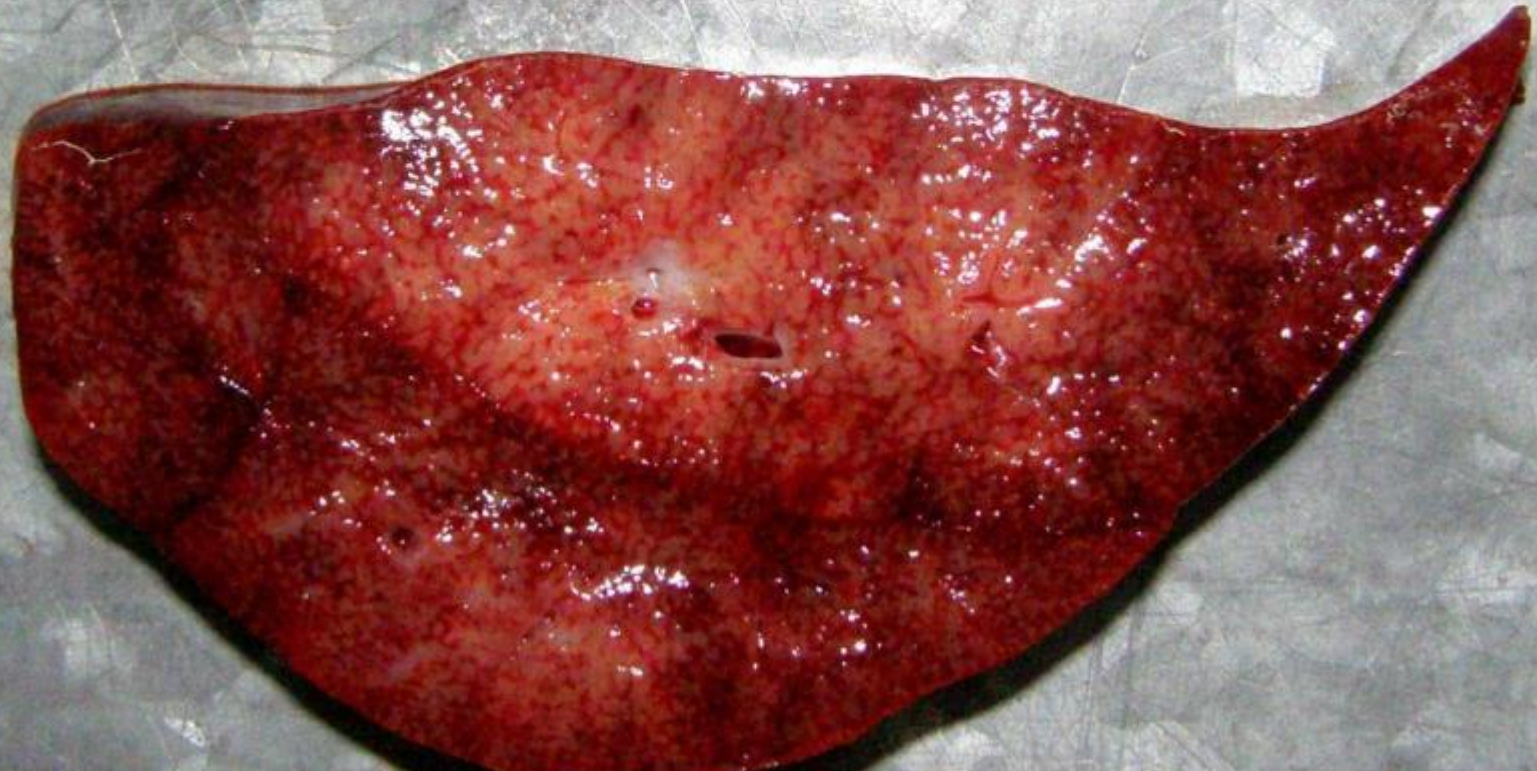


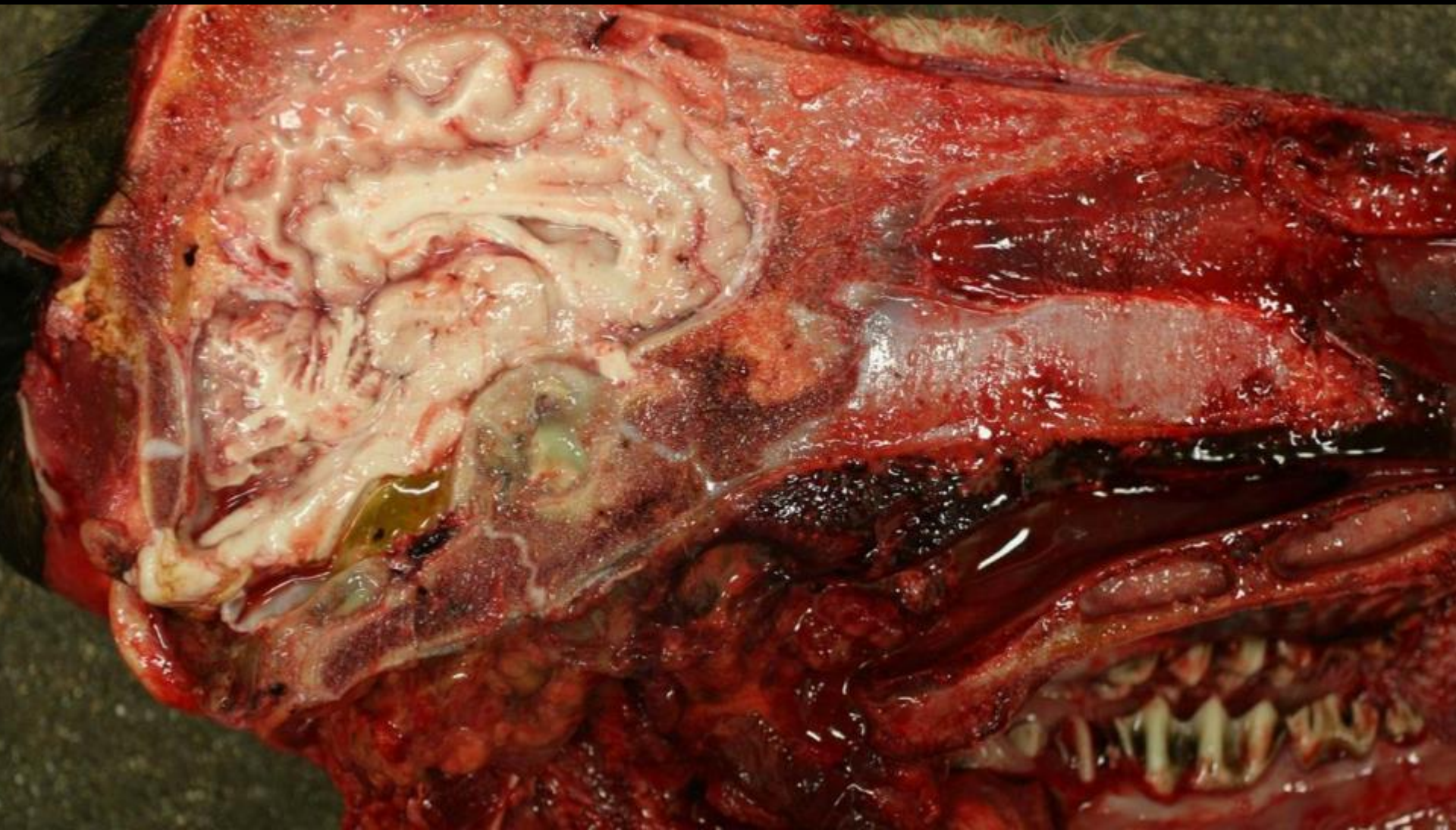


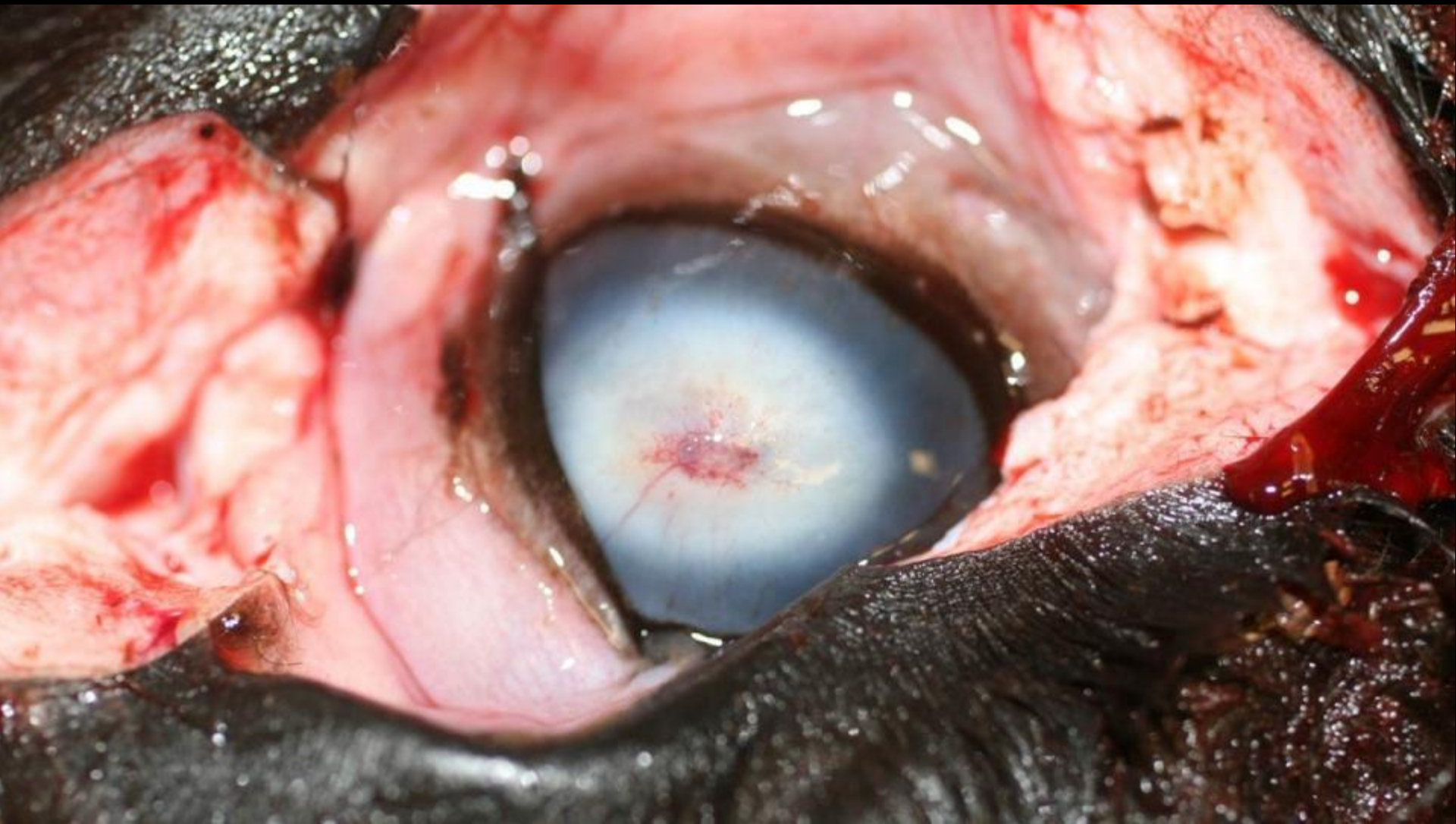


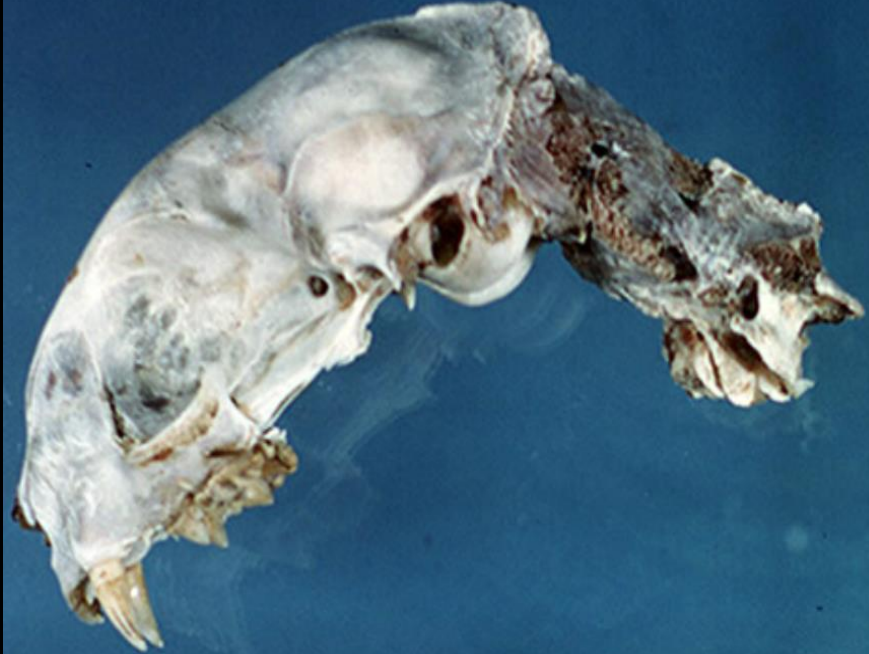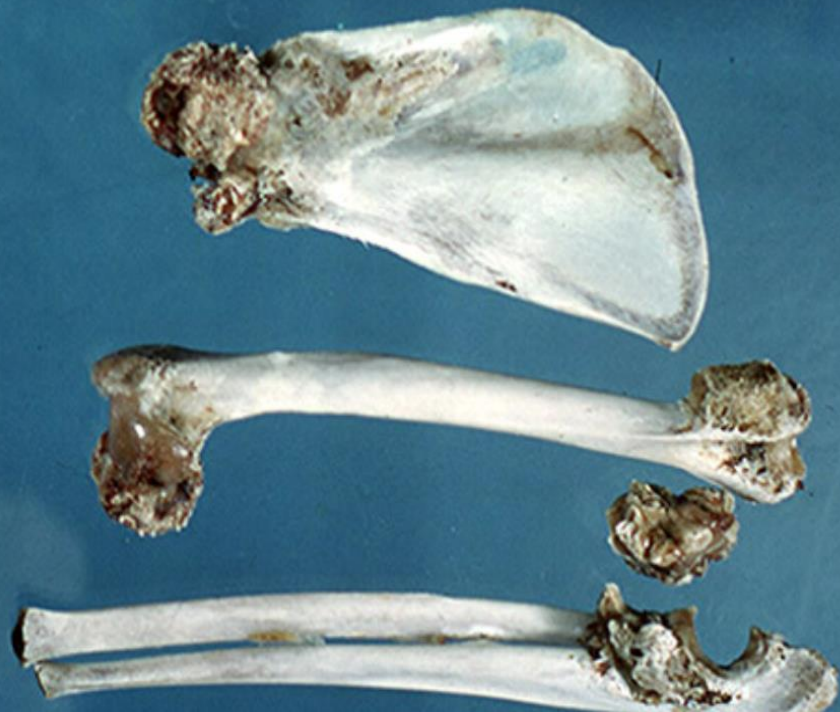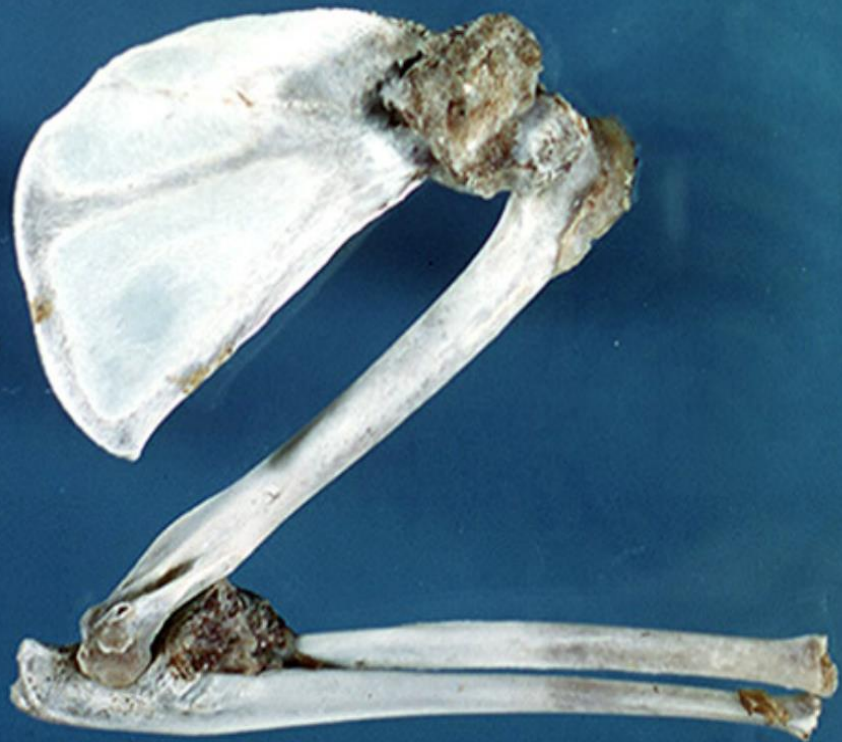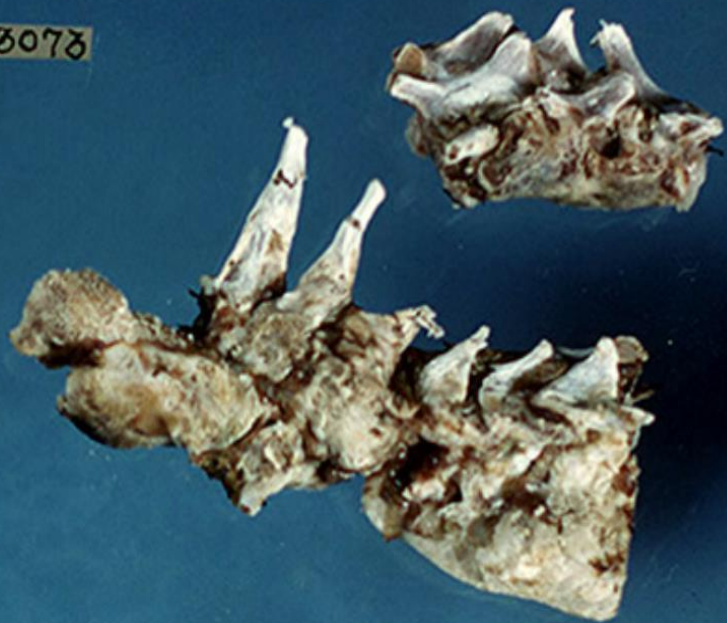


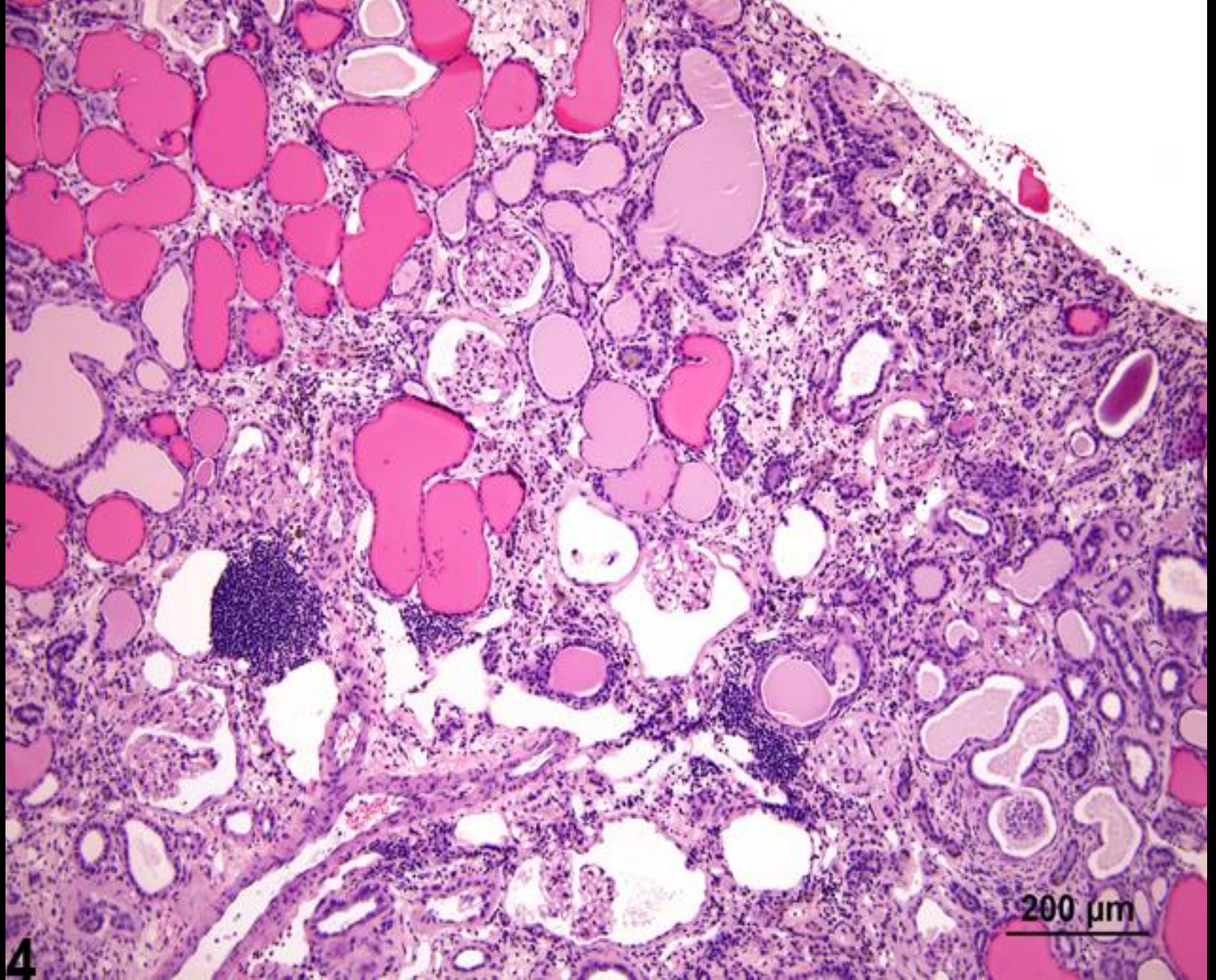






63/6078

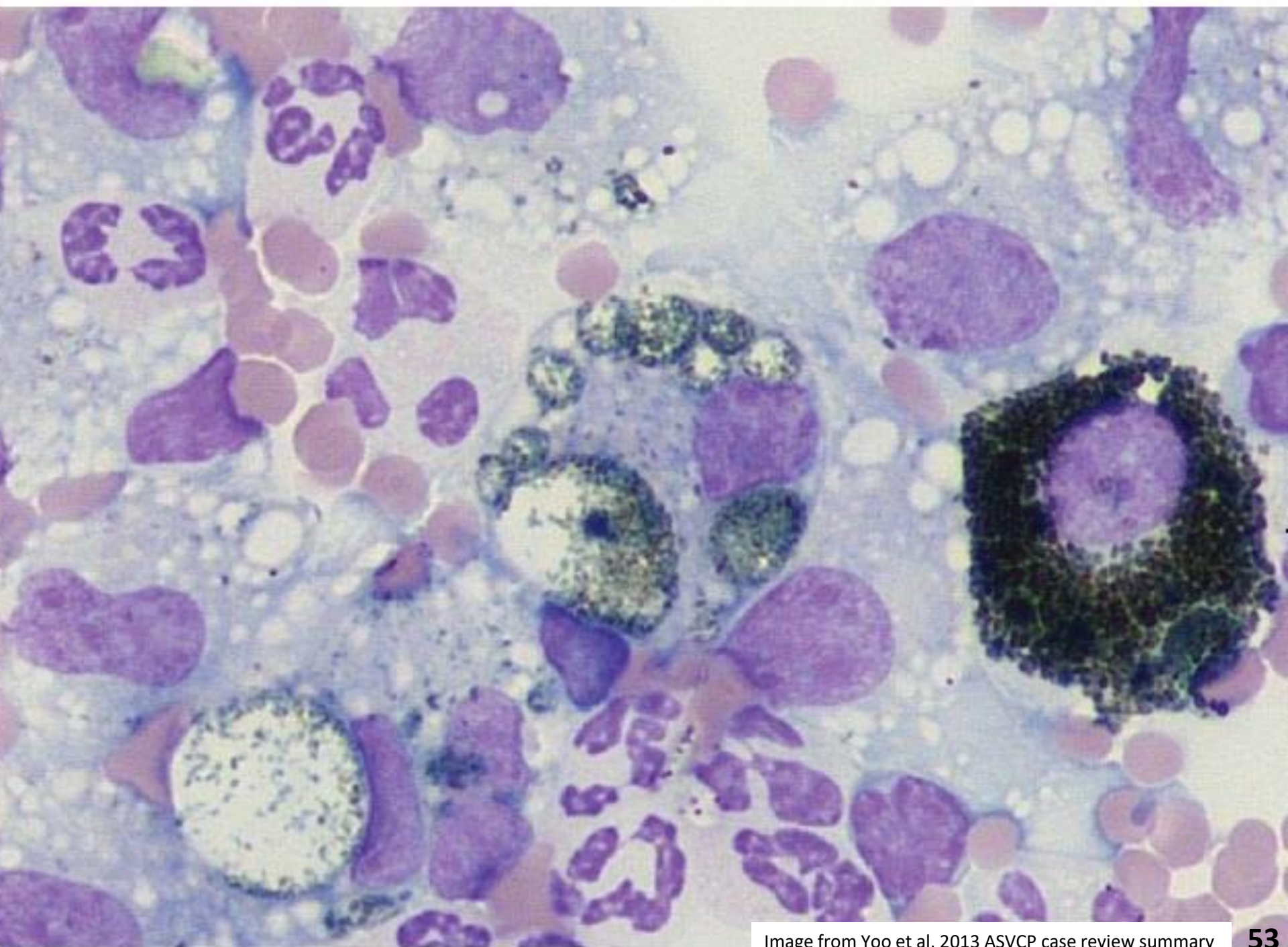


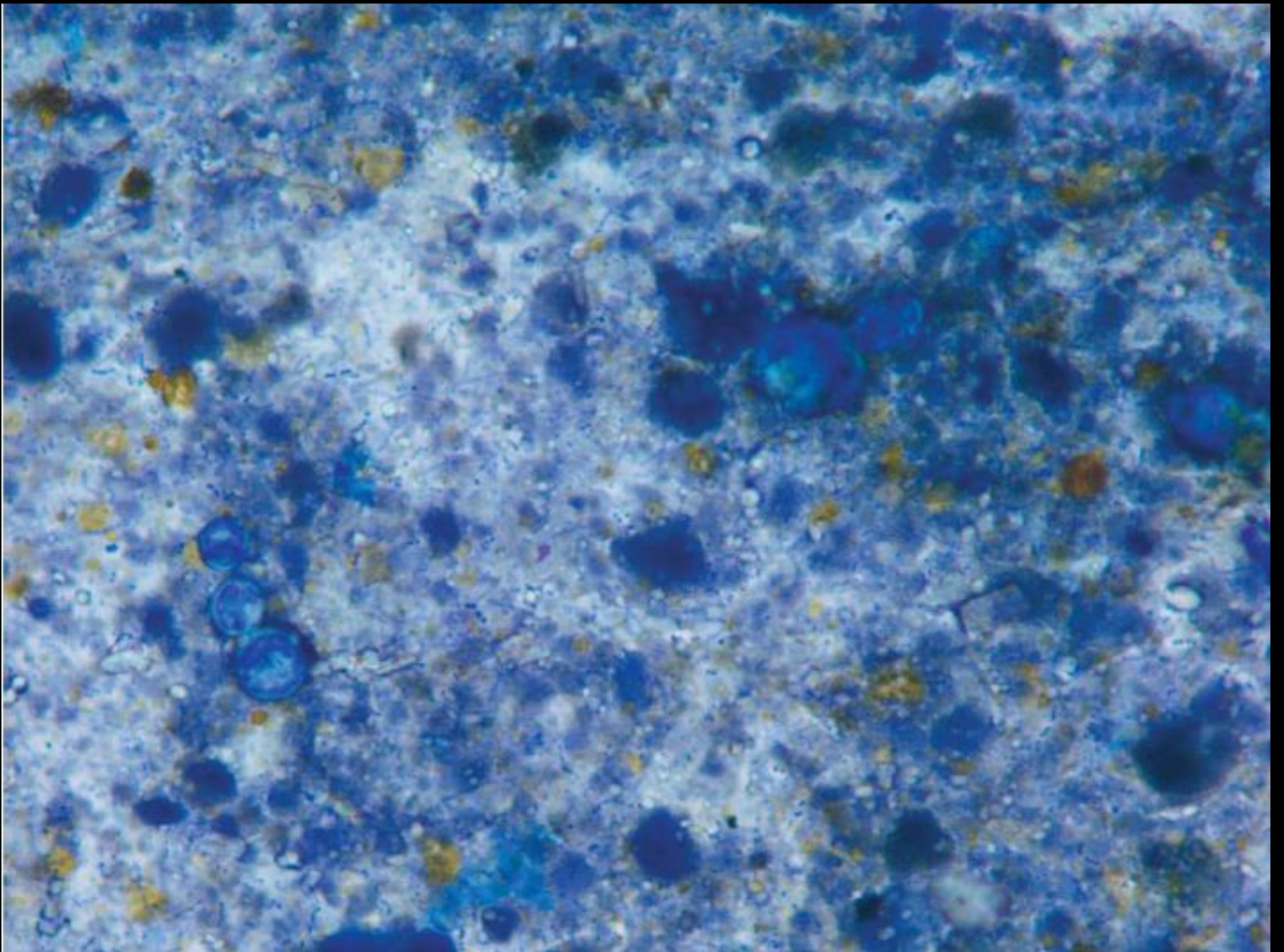


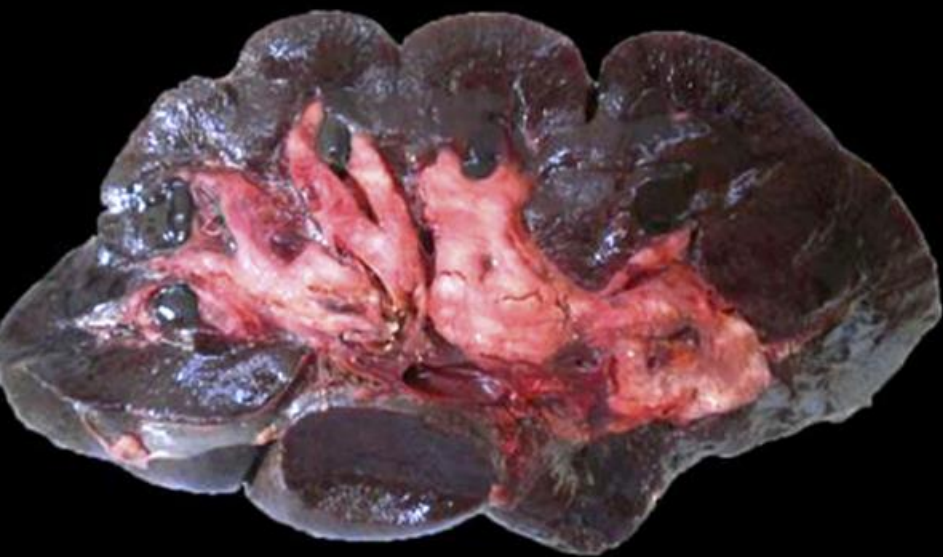
4

200 μ m

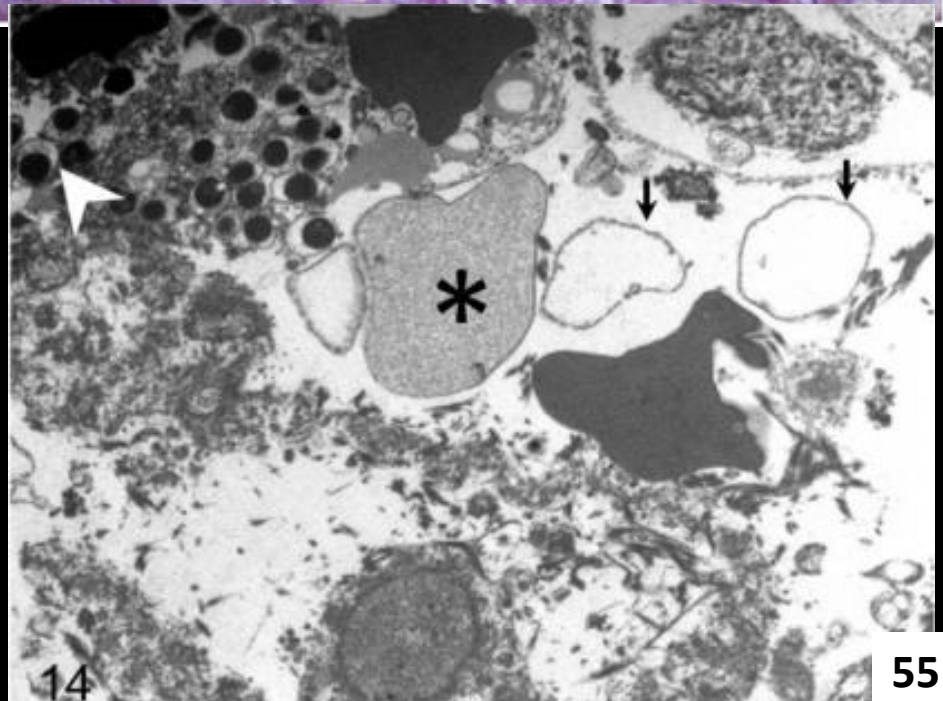
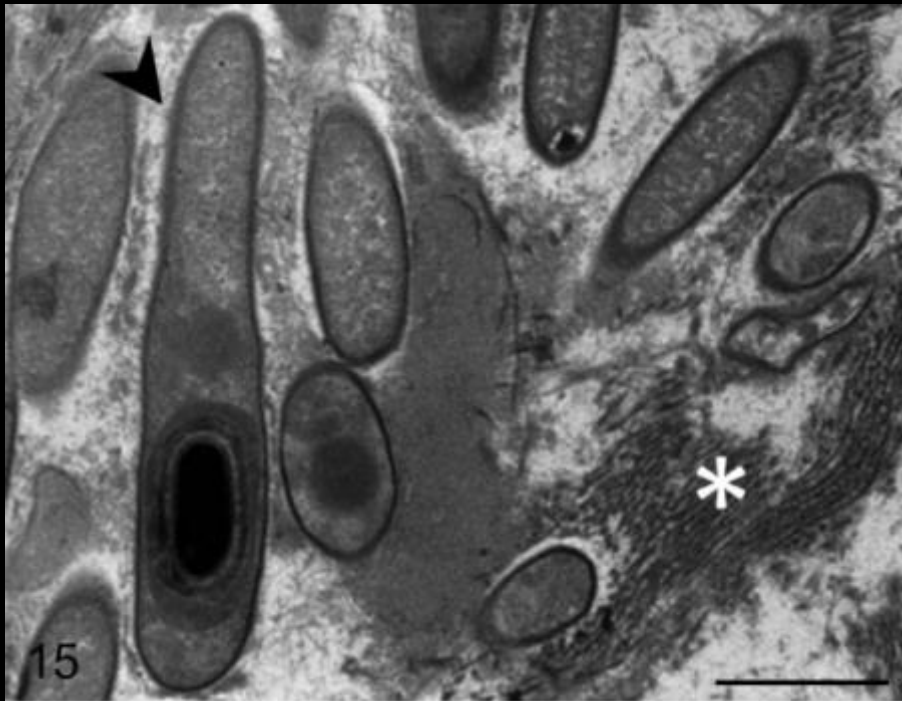
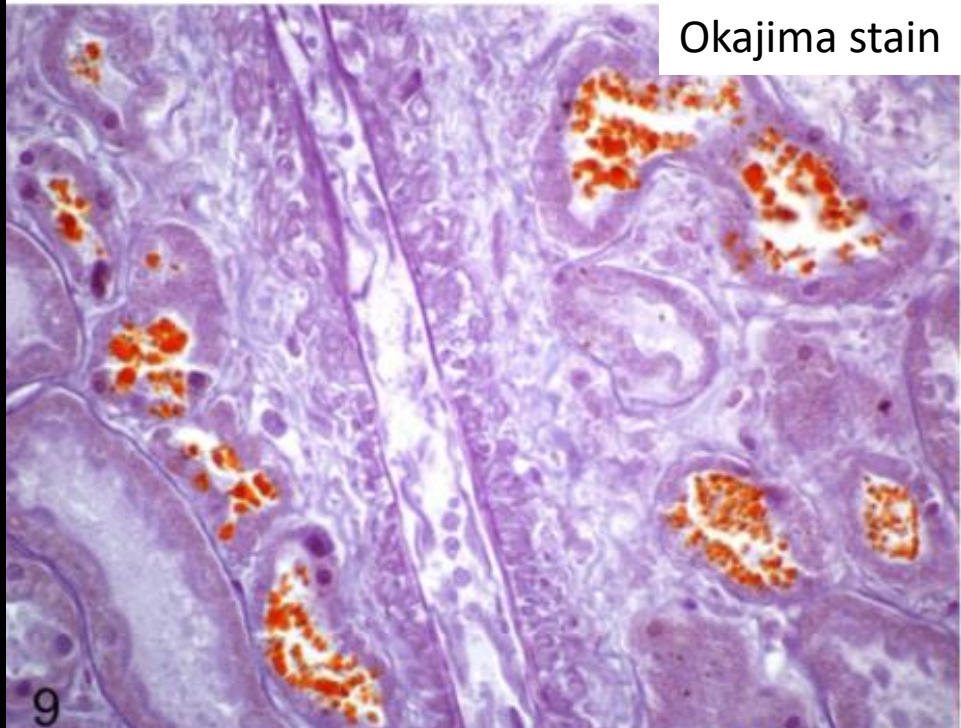
52

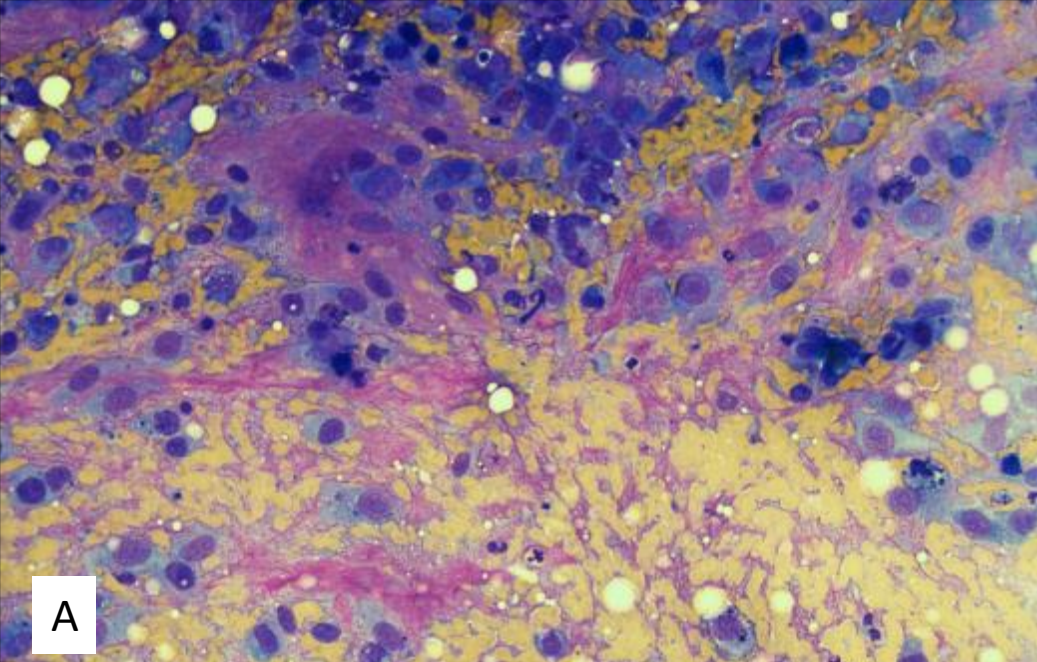




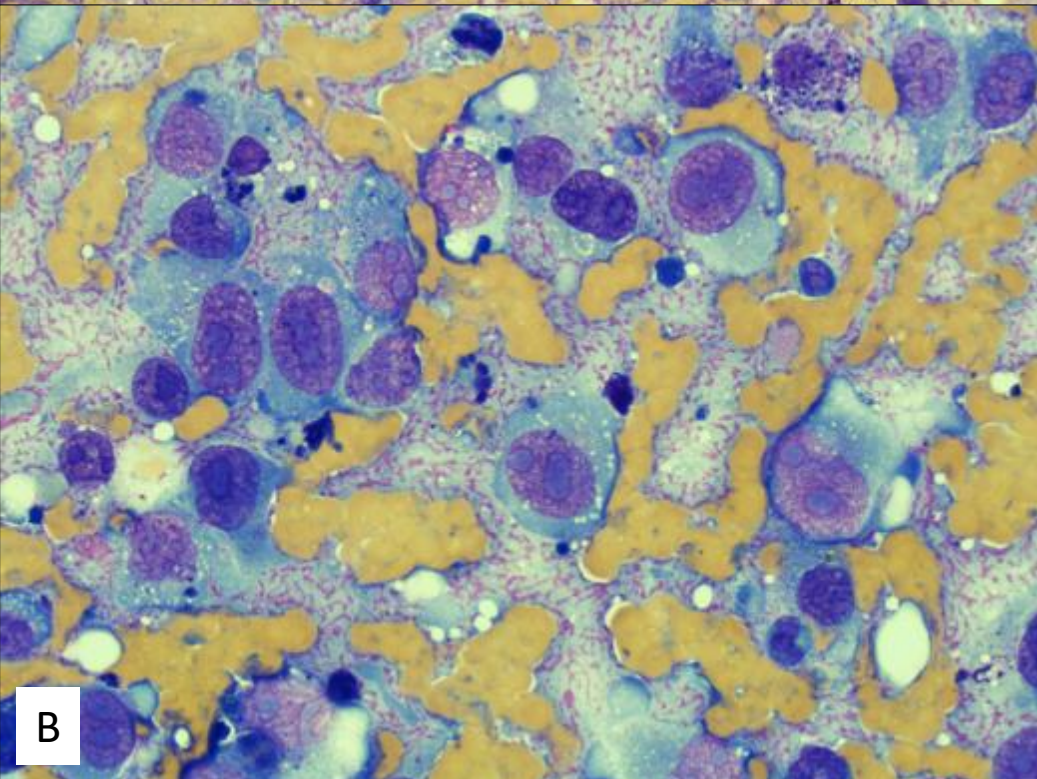


4

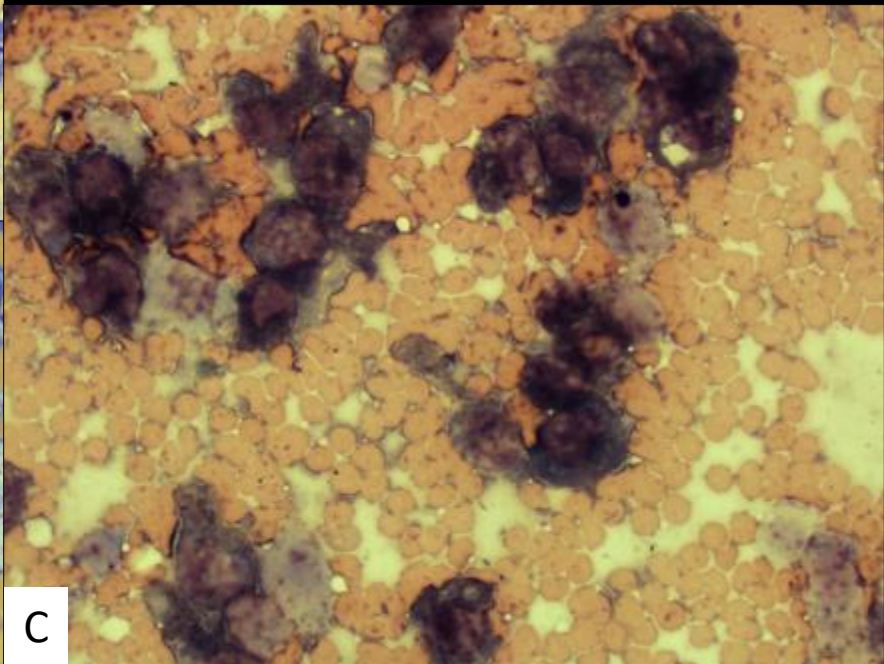




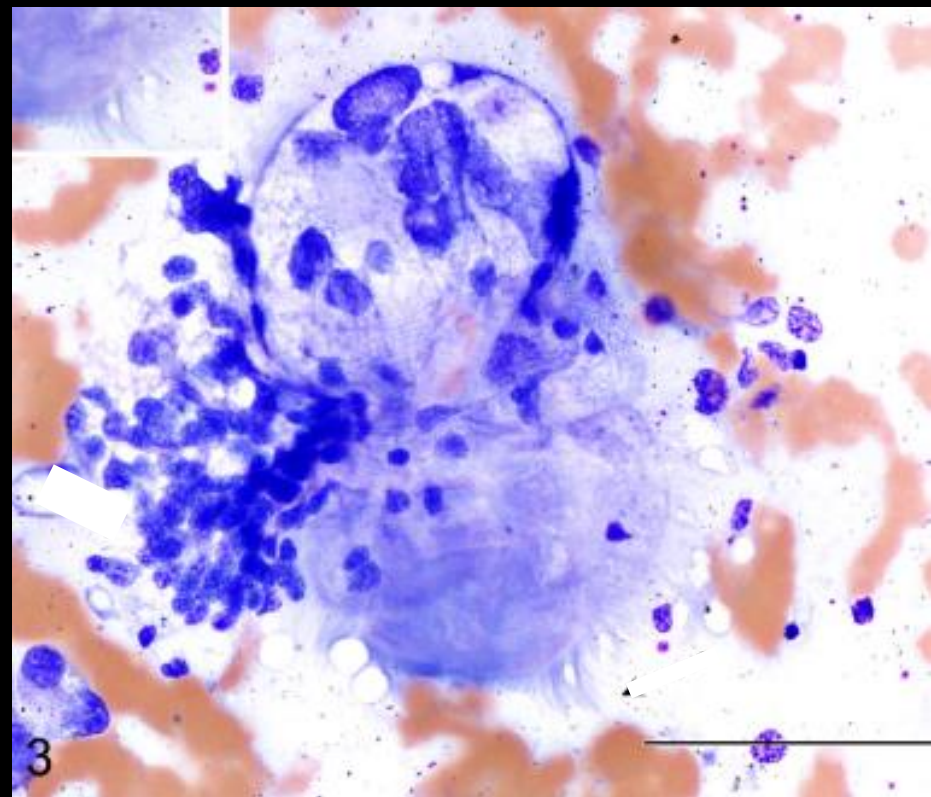
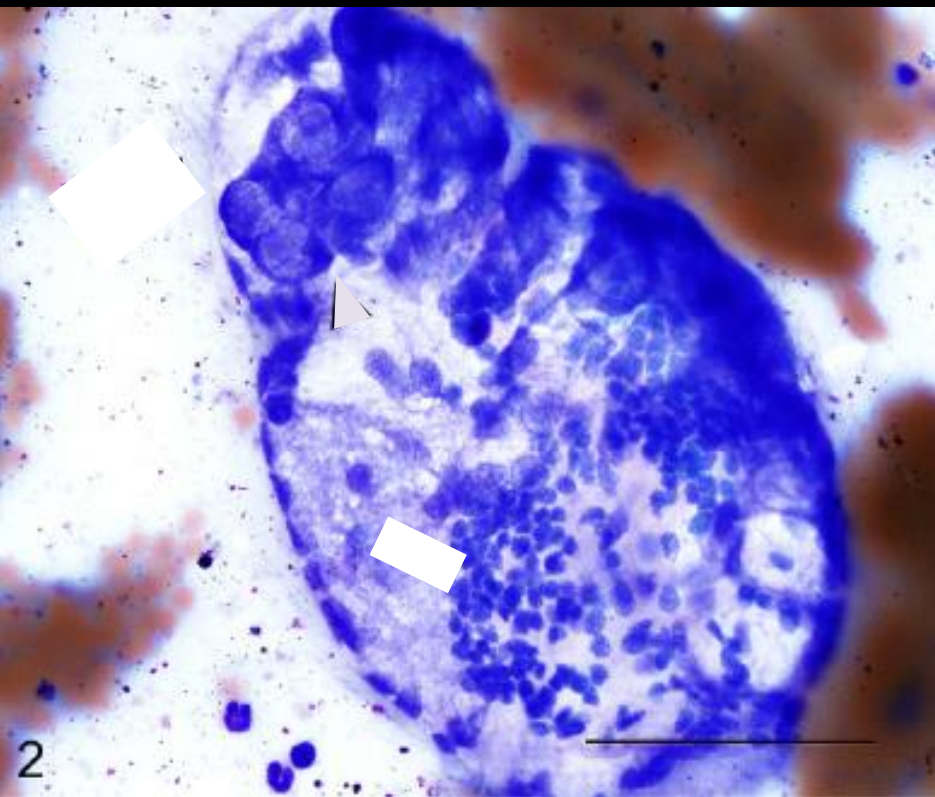
A

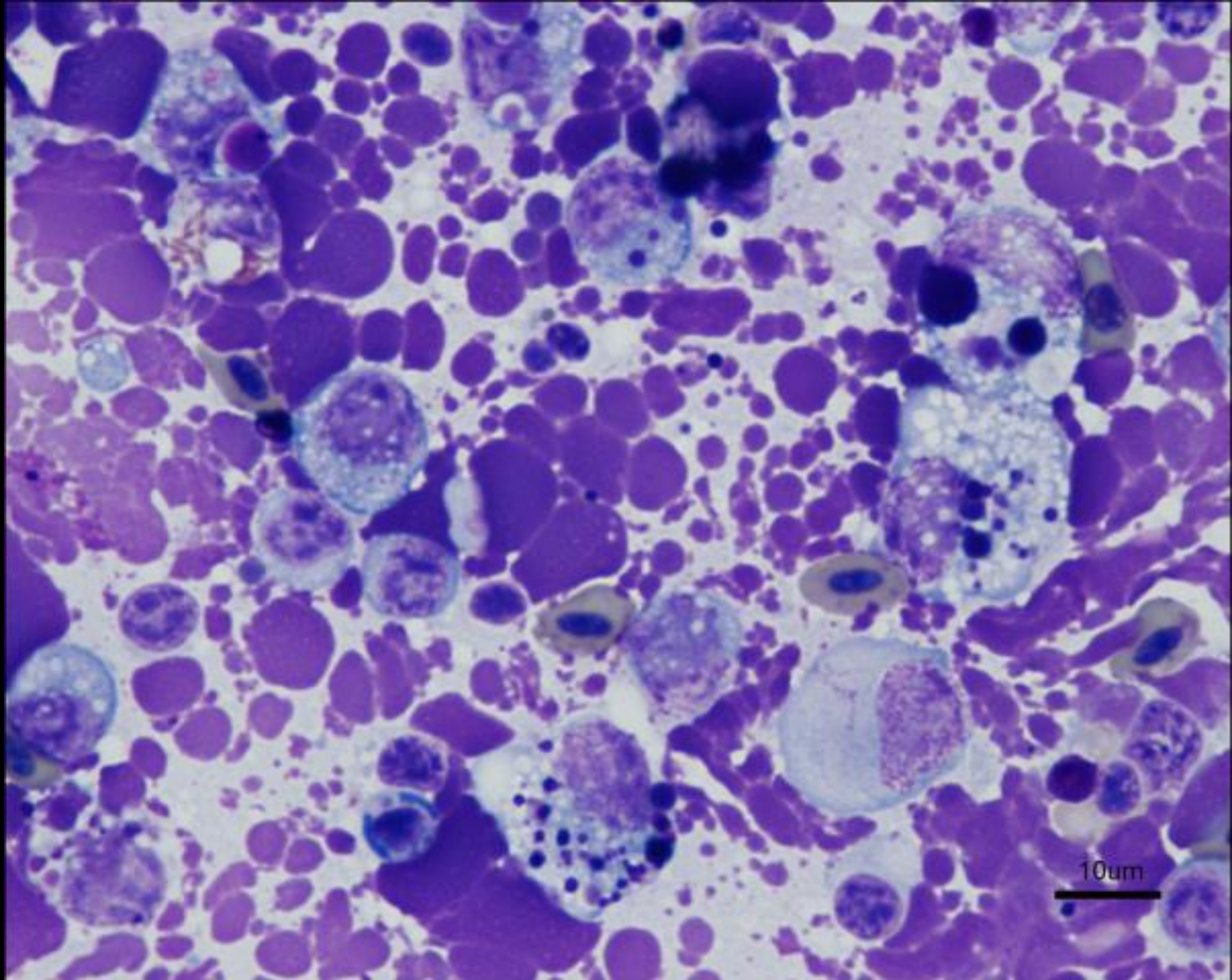


B

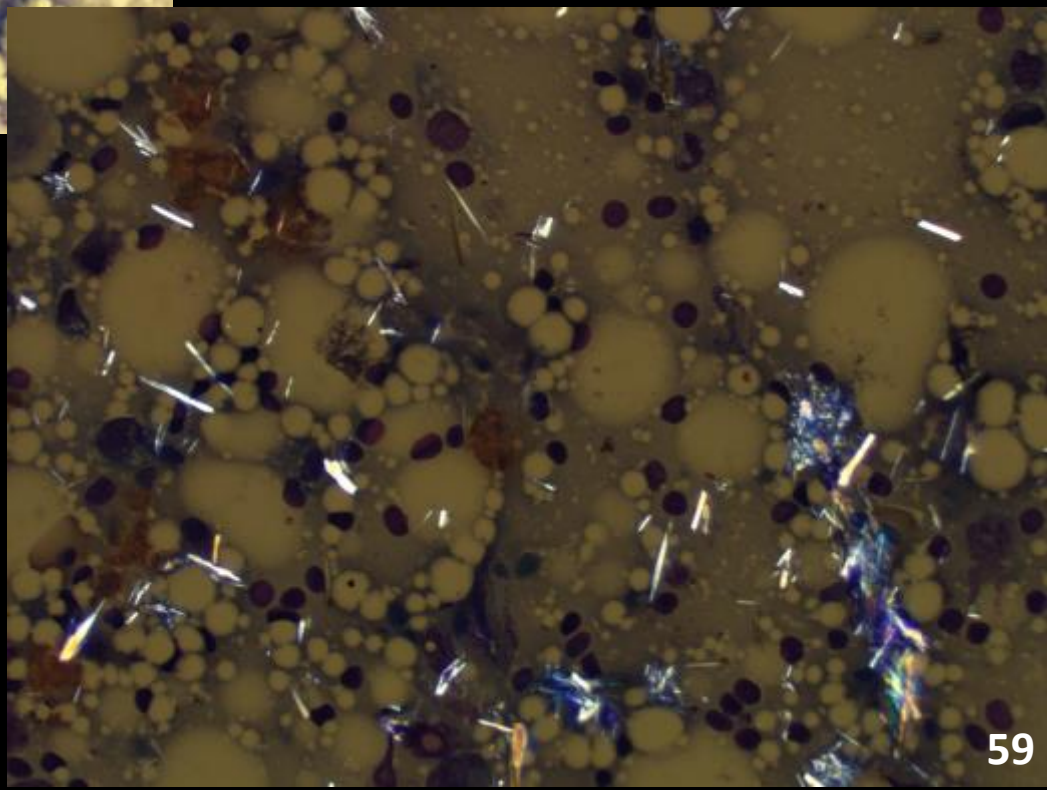
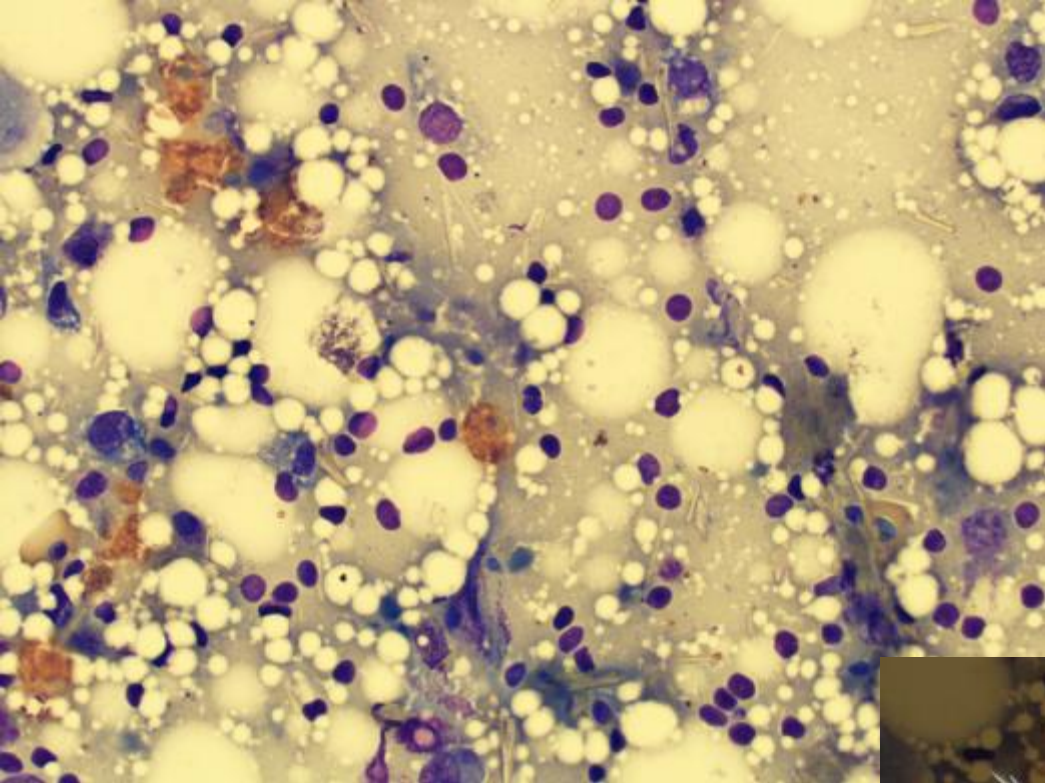


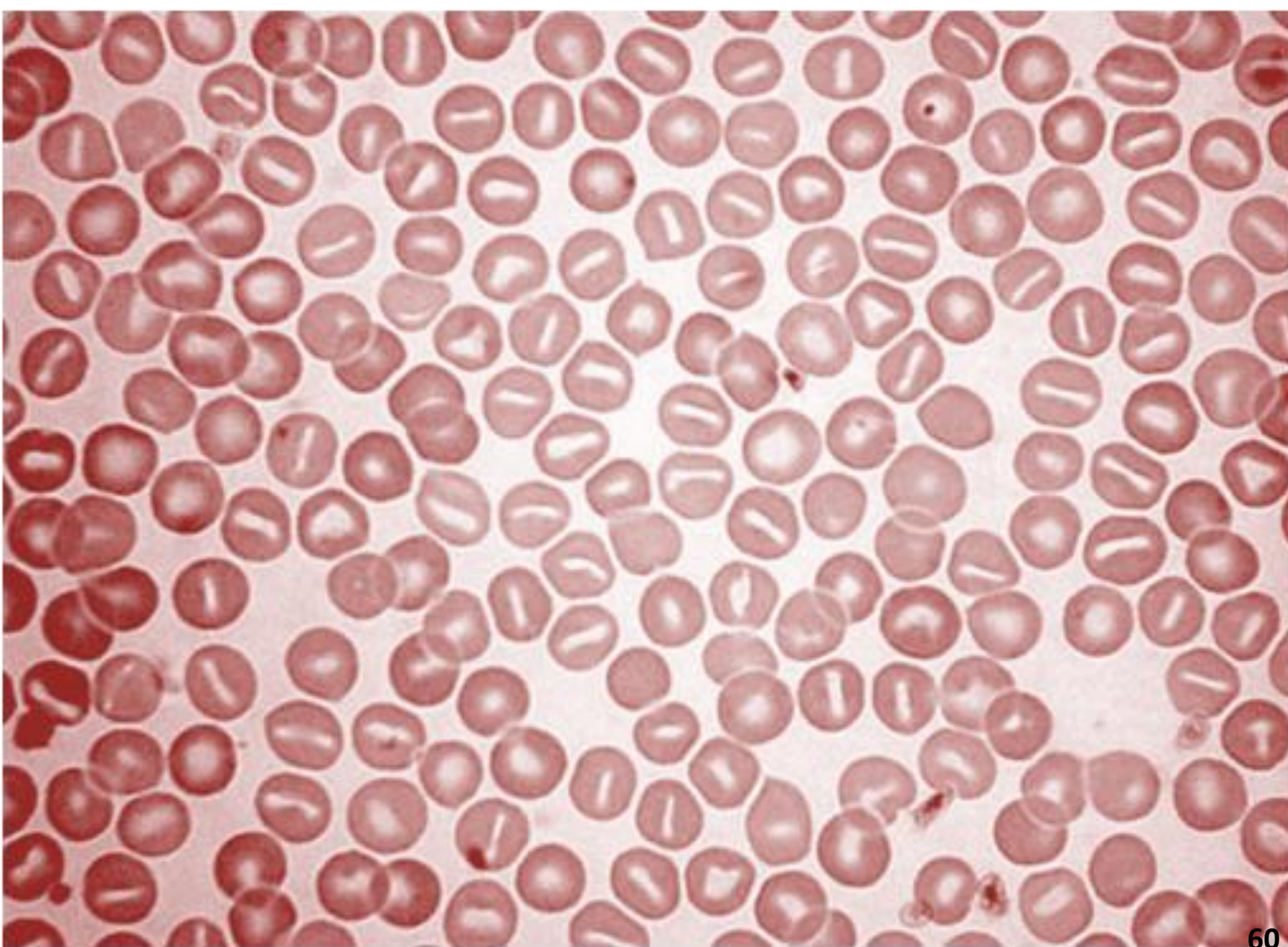
C

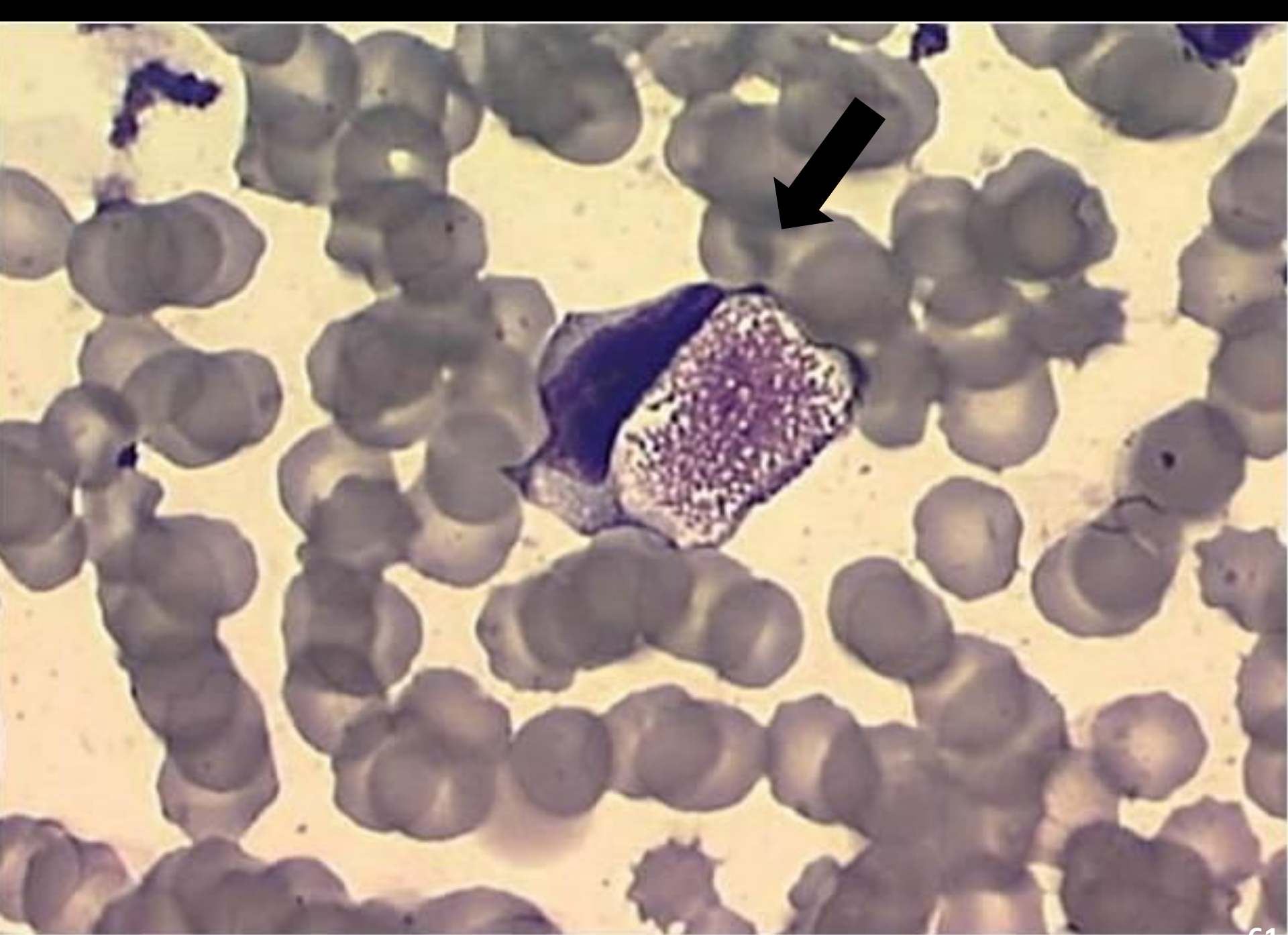


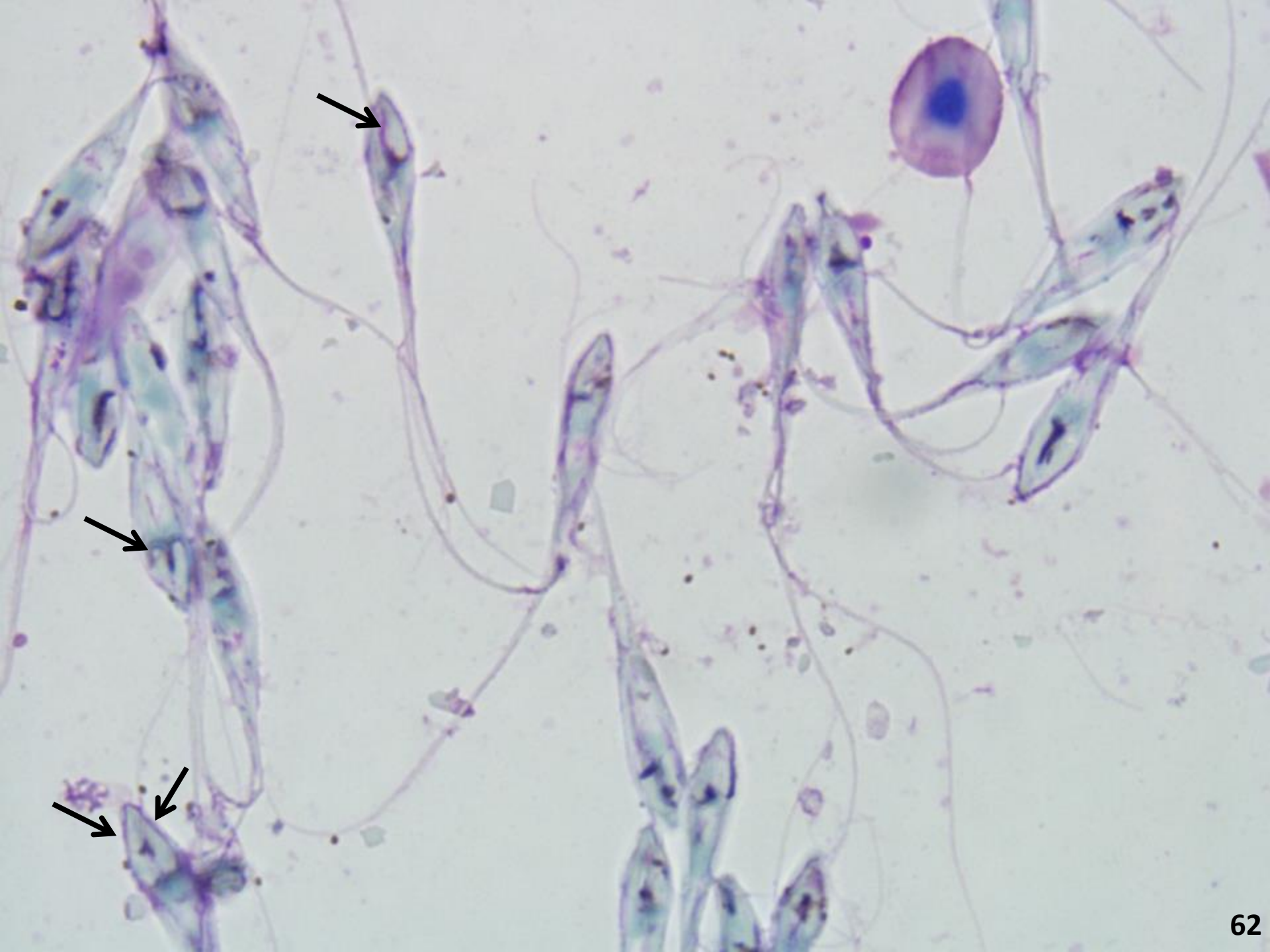


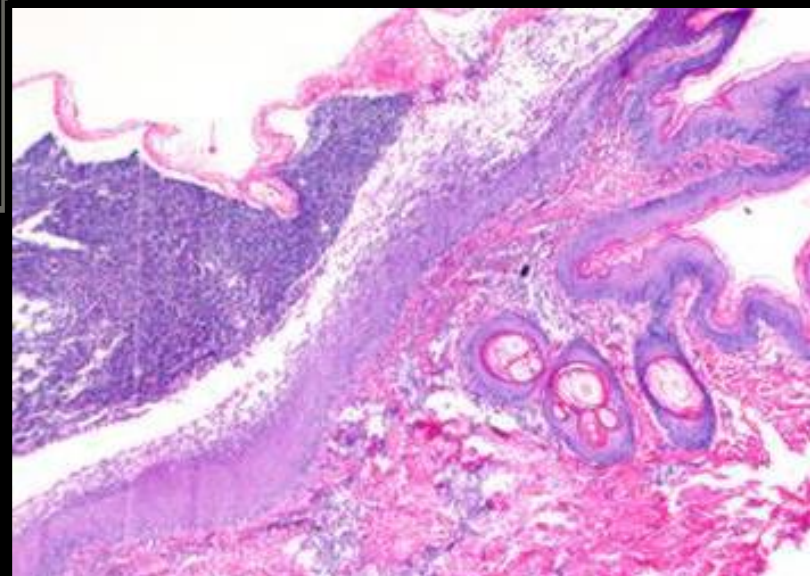
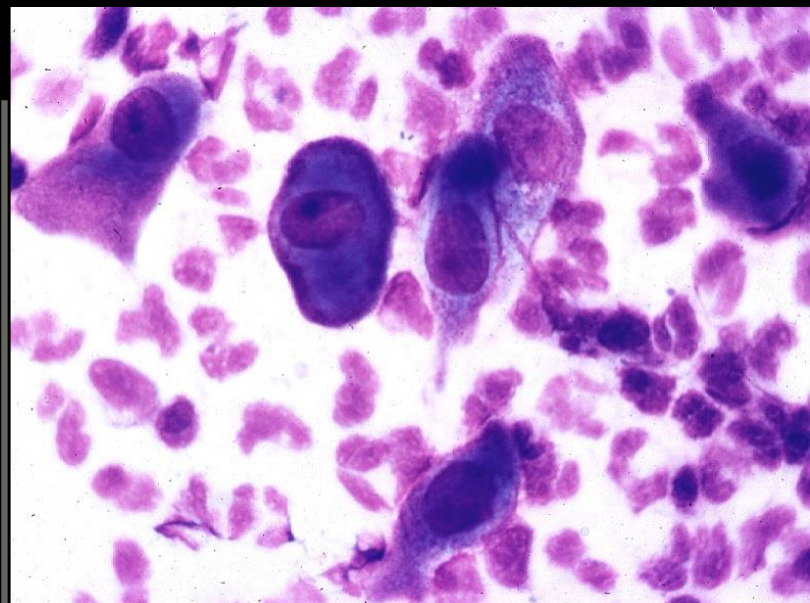
10um

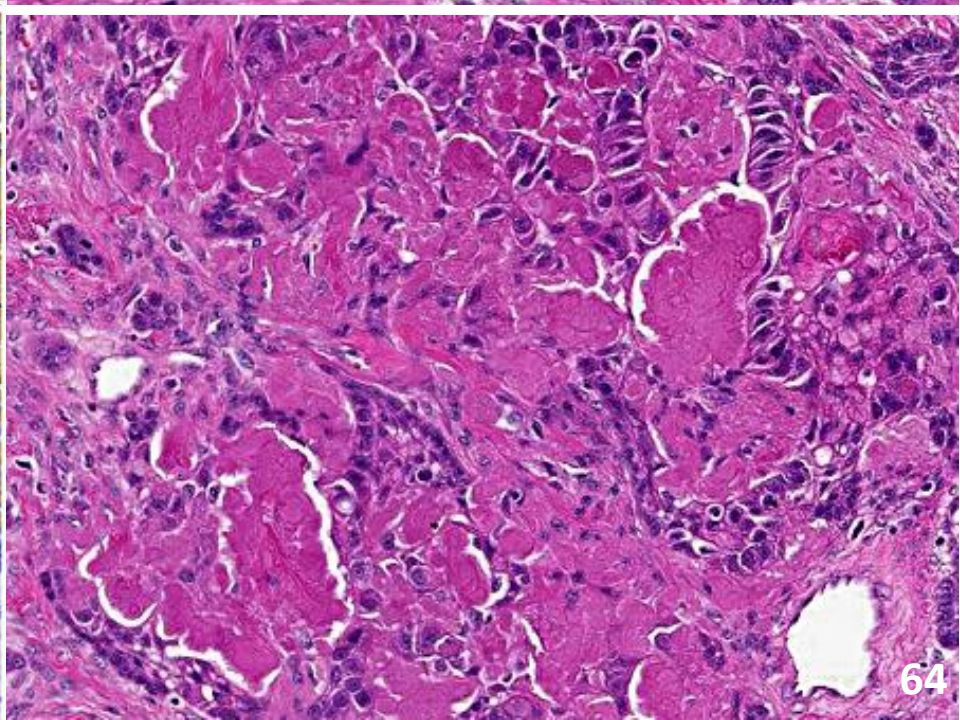
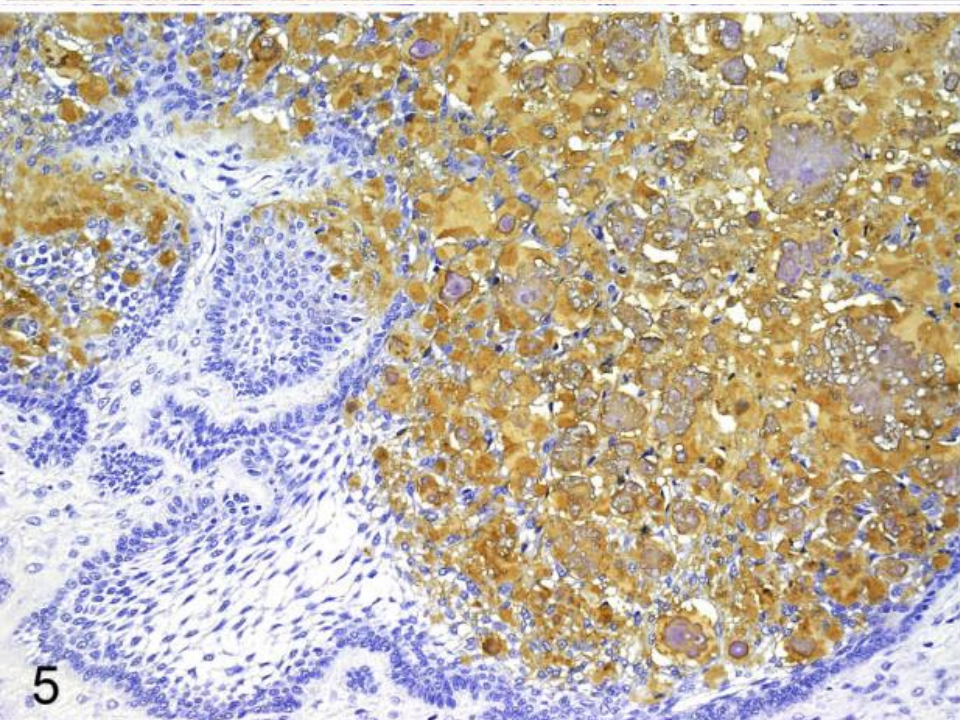
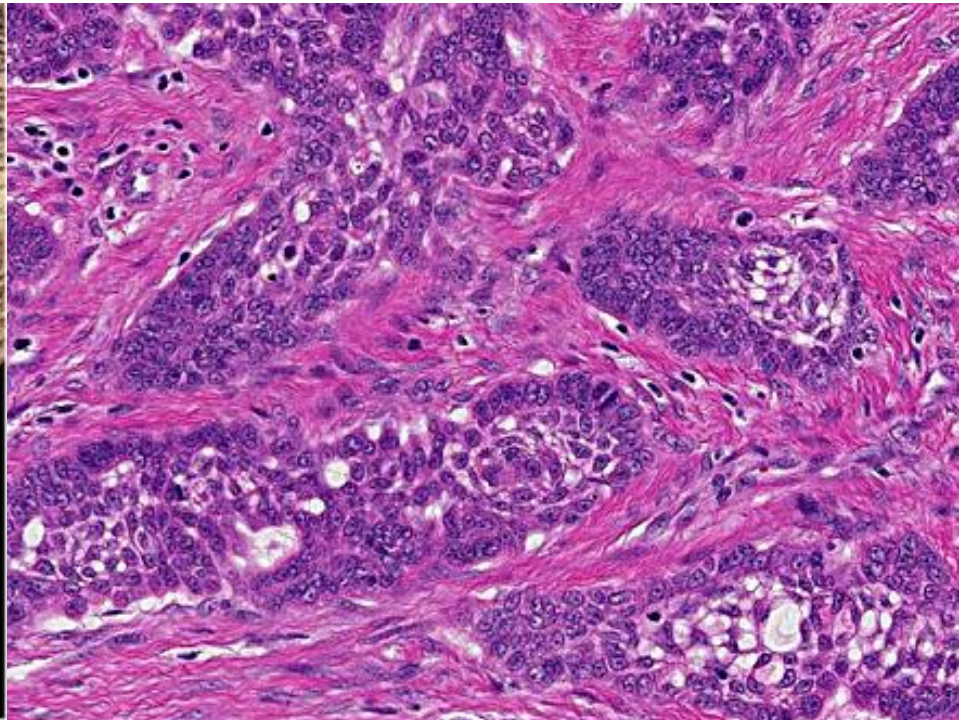


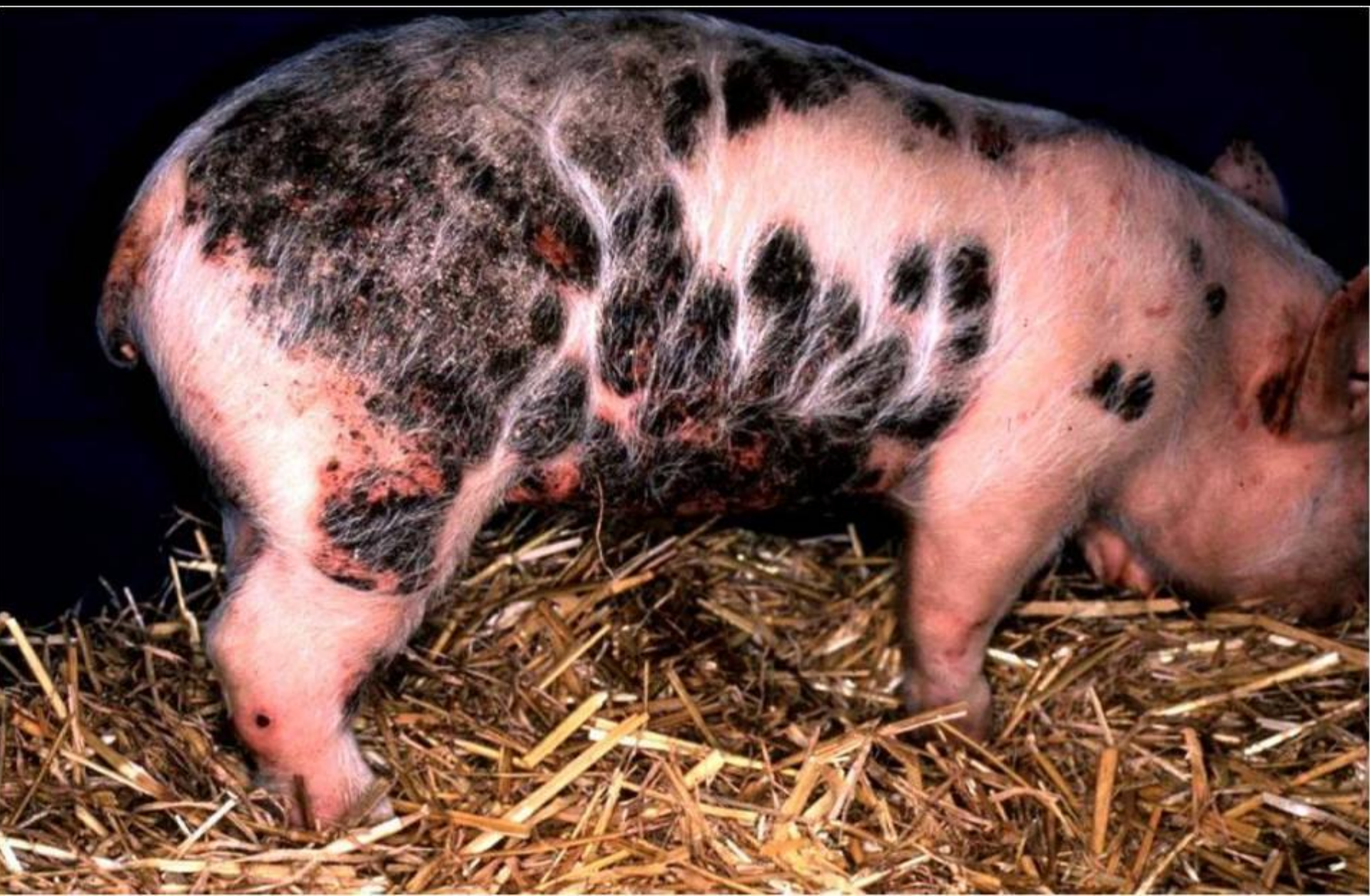

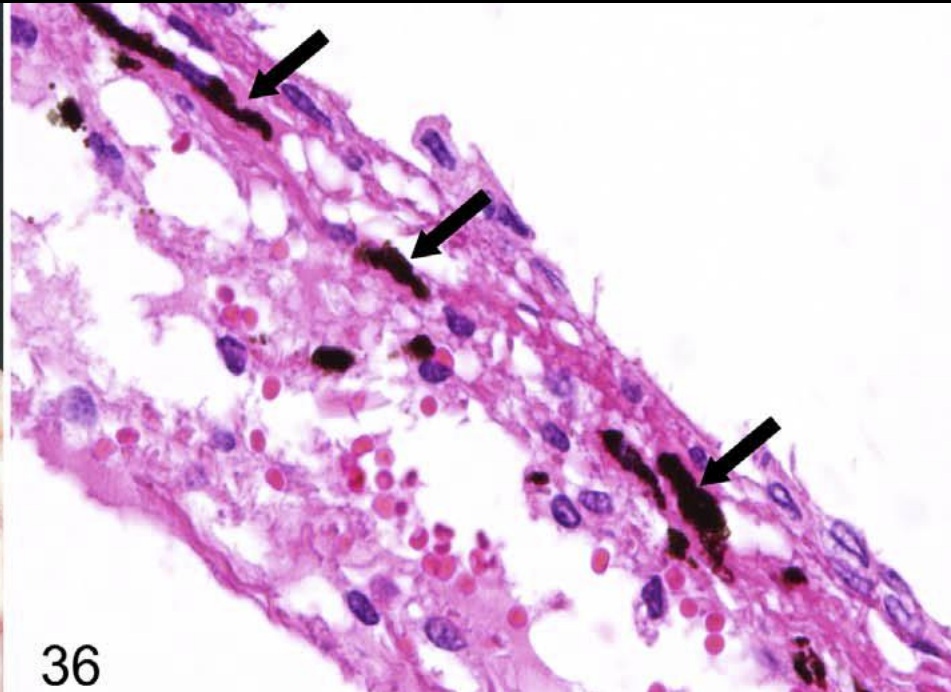

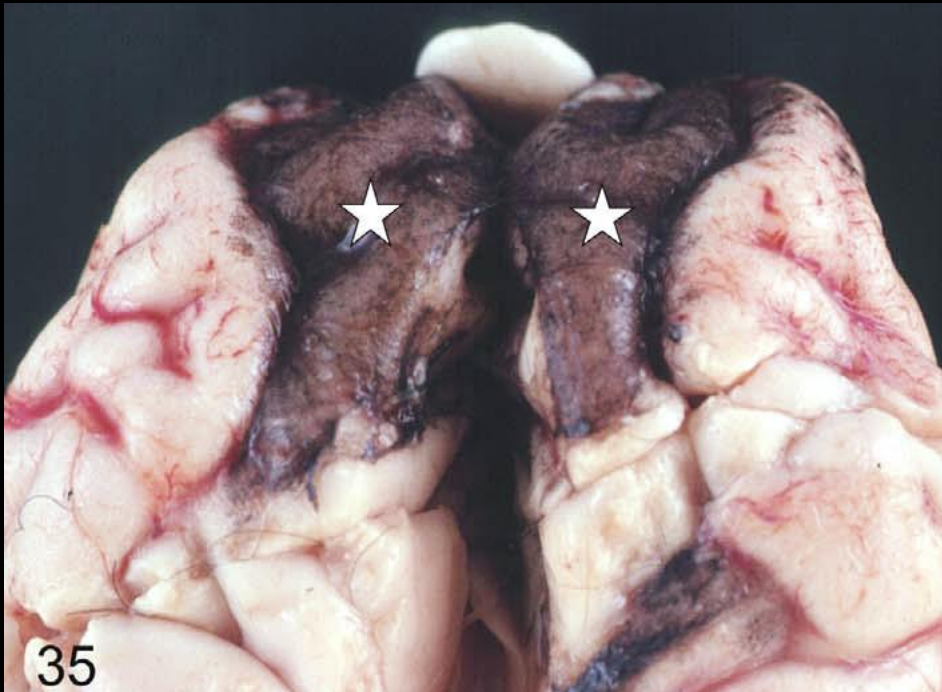


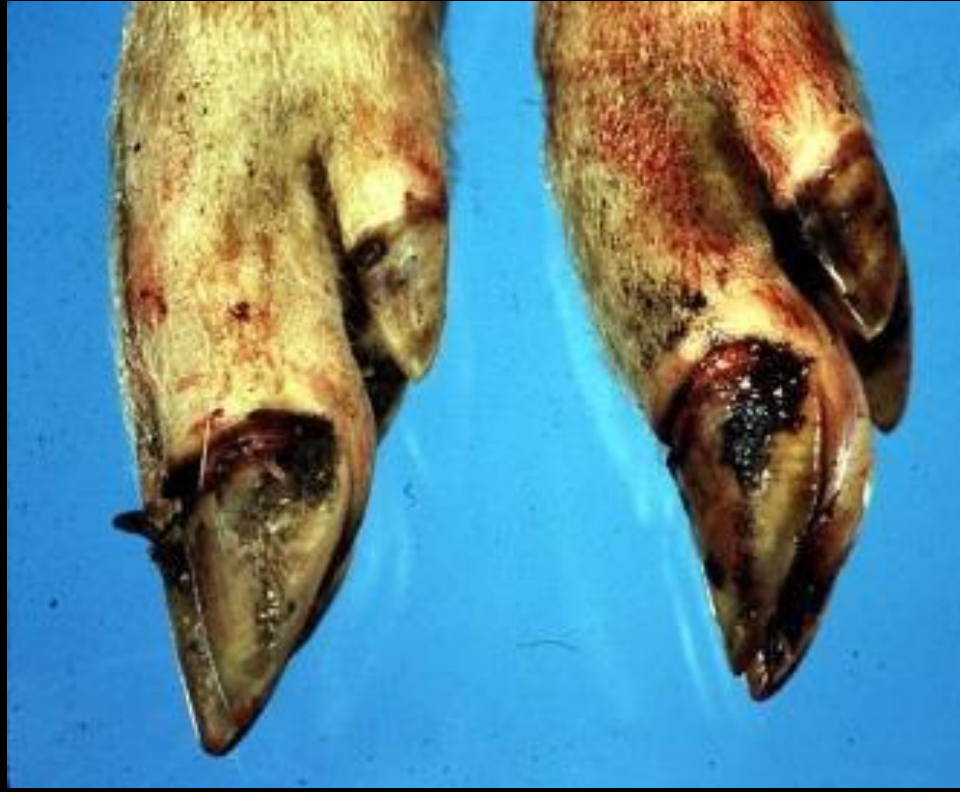
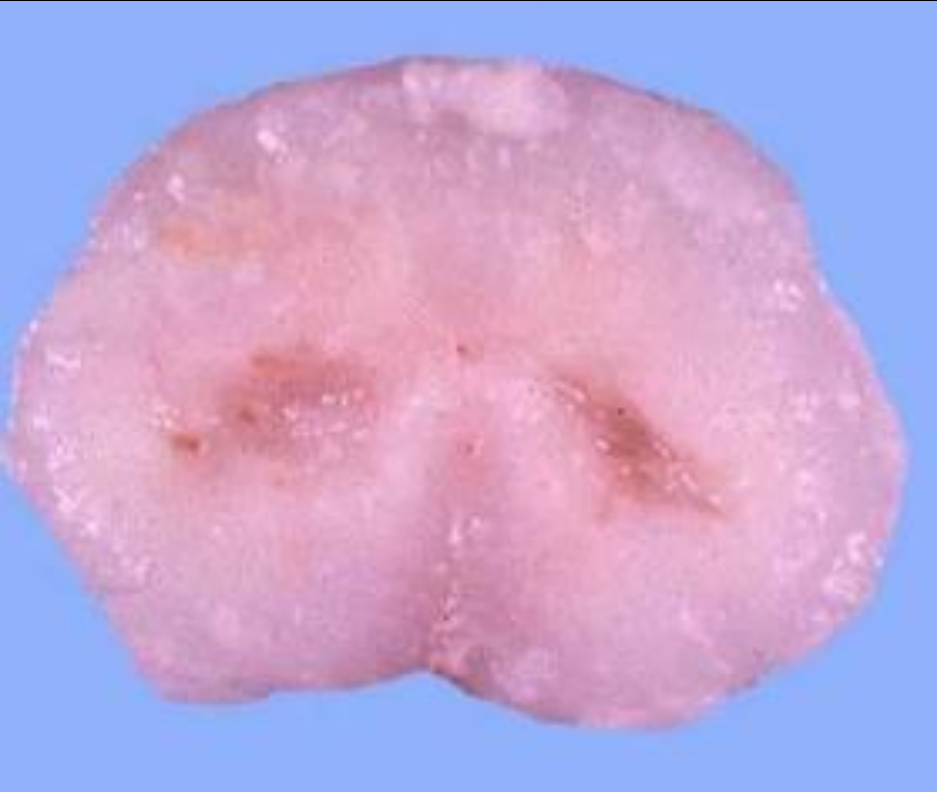


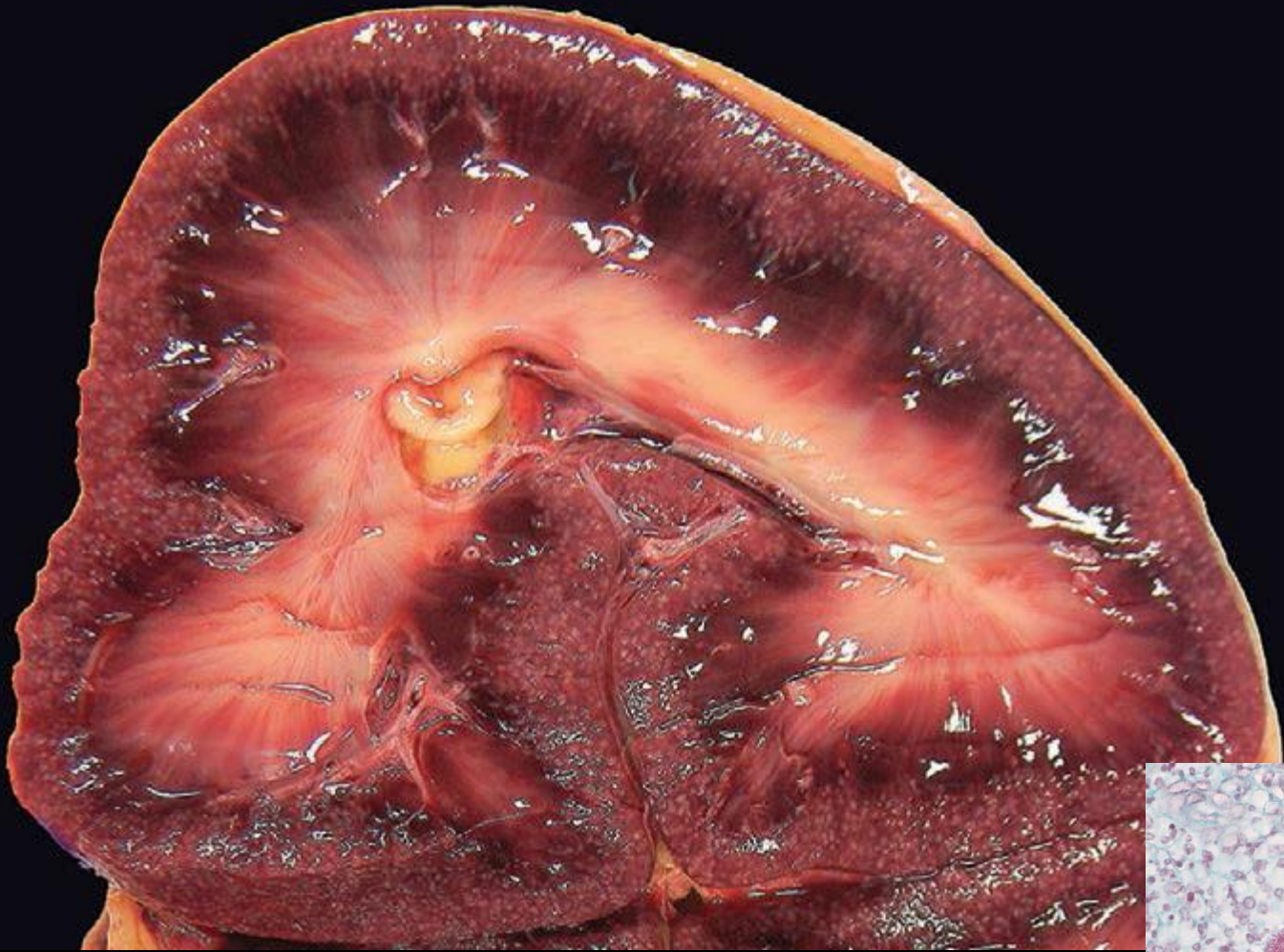







Gram stain

